



WEBINAR-INSPIRED EBOOK

# Maximize Patient Outcomes and Practice Profitability with Robotic Laser Technology

Kile Kaspar, D.C. reviews photobiomodulation therapy research and case studies from her practices as she shares how Robotic MLS Laser Therapy technologies can improve clinical results and practice profitability.

Watch the webinar that inspired this eBook on the [Cutting Edge Knowledge Center](#).

# About Dr. Kaspar

Energy in Motion ◇ Shawnee, Kansas

Dr. Kile Kasper is a chiropractic physician with over 22 years of experience, specializing in photobiomodulation therapy for over two decades.


Her journey began 34 years ago when she suffered traumatic brain, pons, spinal cord and cervical disc injuries in addition to locked-in syndrome. Against overwhelming odds, she defied medical expectations and emerged a miracle.

Having exhausted every conventional avenue of treatment, from physical therapies to medications, her symptoms persisted. Faced with the prospect of a wheelchair by age 50, she embarked on a quest for a solution, which ultimately lead her to chiropractic care and photobiomodulation therapy.

Dr. Kasper's journey mirrors the struggles of countless patients she has encountered over the years. She is proud to offer them Multiwave Locked System® (MLS) Laser Therapy, developed in Italy by the world's foremost authority on light and magnetic therapy.

Embracing chiropractic care as a cornerstone of her own healing journey, Dr. Kasper now stands at the forefront, empowered to transform the lives of countless individuals. Through her practice and her story, she aspires to ignite a ripple effect of healing, envisioning a world where collective efforts can impact millions for the better.





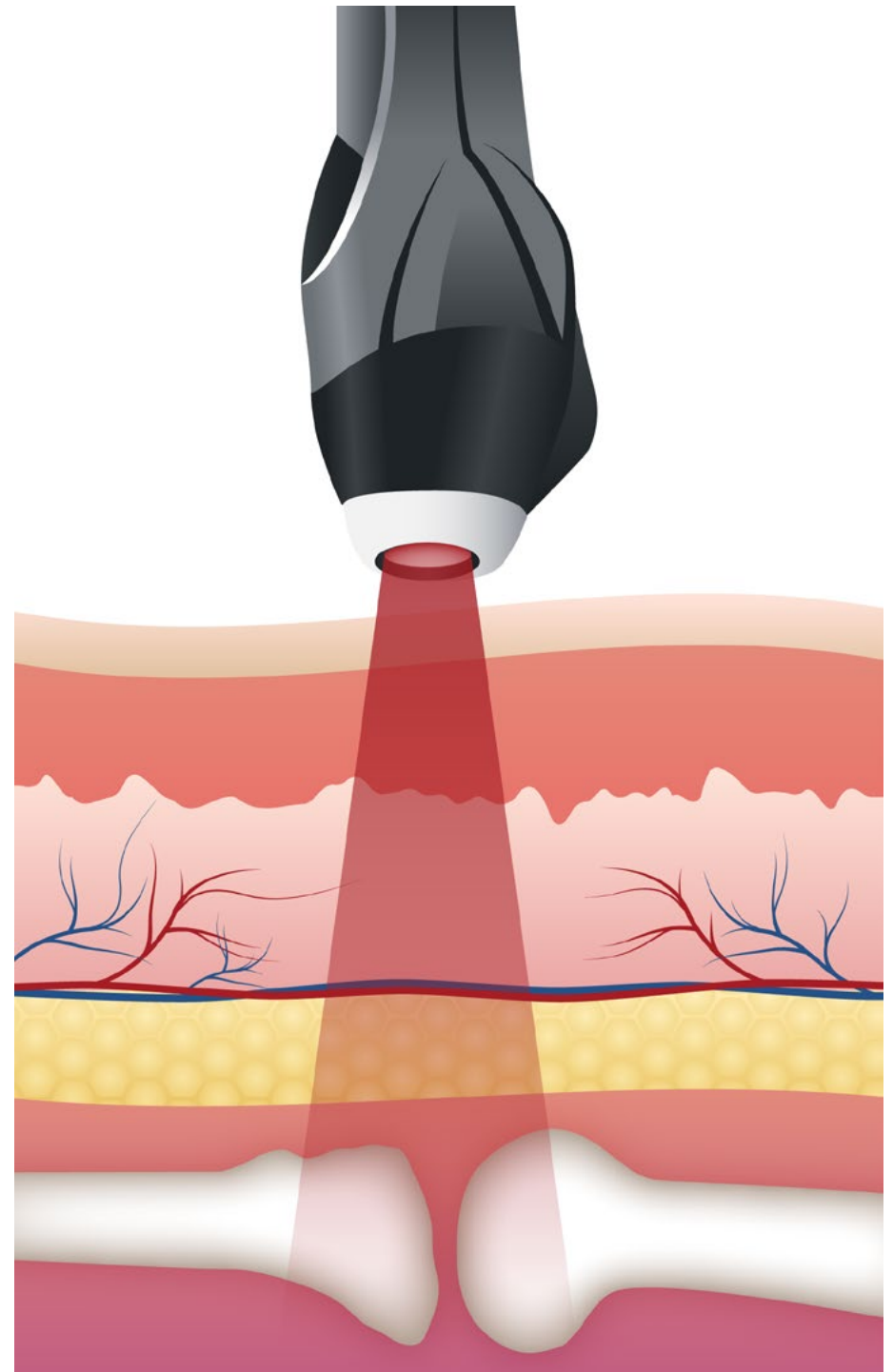
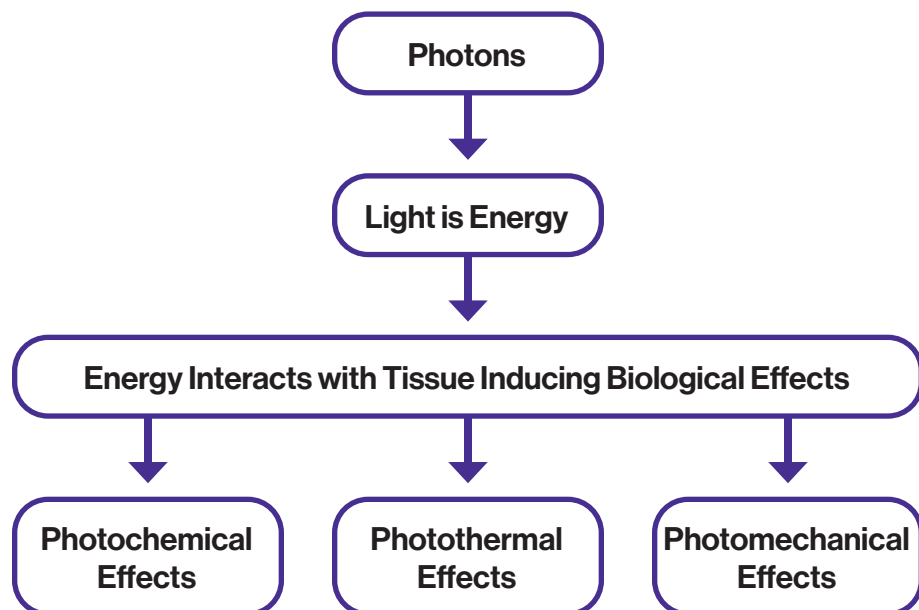
# Table of Contents

Understanding the Basics of Photobiomodulation . . . . .	4	Case Studies . . . . .	12
Laser Classifications. . . . .	5	Dr. Kaspar's Recovery, Complex Cervical Injuries . . . . .	13
Key Indications for MLS Laser Therapy . . . . .	6	Whiplash/Cervical Fracture . . . . .	19
Understanding the Mechanism of Action of Photobiomodulation . . . . .	7	Supraspinatus Tear . . . . .	20
Photobiomodulation Research. . . . .	8	Traumatic Brain Injury. . . . .	21
In Vivo Research, Nerve Regeneration . . . . .	9	Sciatica . . . . .	24
In Vivo Research, Muscle Recovery. . . . .	10	Wound Healing . . . . .	27
Case Report, Cervical Radiculopathy . . . . .	11	Before and After Treatment Images . . . . .	30
		Practice Benefits. . . . .	35

# Understanding the Basics of Photobiomodulation

Photobiomodulation therapy (PBMT) is a non-invasive treatment that utilizes specific wavelengths of light to stimulate healing at the cellular level, reducing inflammation and relieving pain. This therapeutic approach has gained popularity across various medical disciplines due to its effectiveness with no side effects.

A laser emits a concentrated beam of photons (particles of light) that can penetrate the tissue, where they are absorbed by cellular components known as chromophores. These chromophores, such as cytochrome c oxidase in the mitochondria, respond to light energy by initiating a cascade of biochemical reactions within cells. This leads to increased production of adenosine triphosphate (ATP), the energy currency of cells, along with the release of signaling molecules that modulate inflammation and promote tissue repair.



# Laser Classifications

## and innovations in light-based technologies

The Food and Drug Administration (FDA) categorizes lasers into four classifications. Most therapy lasers are classified as Class III or Class IV. Drawing from over two decades of experience, Dr. Kaspar sheds light on the nuances between these classifications and advancements in laser technologies.

**Class III Lasers**, often referred to as cold lasers or low-level light therapy (LLLT), operate at lower power levels and do not significantly raise tissue temperatures. While they can be effective for managing certain conditions, their limited power output may pose challenges in providing optimal therapeutic doses to deep tissues within reasonable amounts of time.

**Class IV Lasers** boast higher power levels and a greater potential working depth of laser energy. However, this increased power comes with a heightened risk of potential thermal injury to the tissue, particularly in the hands of inexperienced users. Dr. Kasper acknowledges the importance of safety considerations, especially when utilizing lasers with such potential for harm.

In an attempt to surpass the limitations of traditional LLLT while mitigating the potential hazards of higher power therapy lasers, the Multiwave Locked System® (MLS) was born.

Based on over 30 years of research and development, MLS Therapy Lasers are at the forefront of medical innovation, introducing a new era of Class IV lasers.

Utilizing a patented pulse pattern, these unique lasers precisely synchronize a continuous 808nm wavelength emission with a pulsed 905nm wavelengths emission, offering a comprehensive approach to pain management and tissue repair while optimizing safety.

### ◆ Continuous 808nm

Decreases inflammation by stimulating blood flow and lymphatic drainage, inducing the reabsorption of fluid buildup, and interacting with the synthesis and degradation of inflammation mediators.

### ◆ Pulsed 905nm

Affects the transmission of pain at the level of superficial nociceptors and on the afferent nervous fibers. This results in an increase of the cell and nervous fiber's stimulation threshold and therefore a reduced sensation of pain.

This unique combination of continuous and pulsed emissions distinguishes MLS Lasers from other Class IV therapy lasers, allowing it to deliver controlled laser energy leading to consistent and repeatable results while minimizing the risk of thermal damage.

As a result of this enhanced safety feature, the MLS emission system is the only Class IV therapy laser system that has been adapted into a fully robotic unit to optimize treatment administration and enhance clinical outcomes.

Equipped with multiple laser diodes and precise mapping capabilities, robotic MLS Therapy Lasers ensure consistent and homogeneous treatment delivery. This precision allows for tailored treatment plans, with energy doses calibrated per centimeter squared, resulting in reproducible outcomes across patients and treatments.

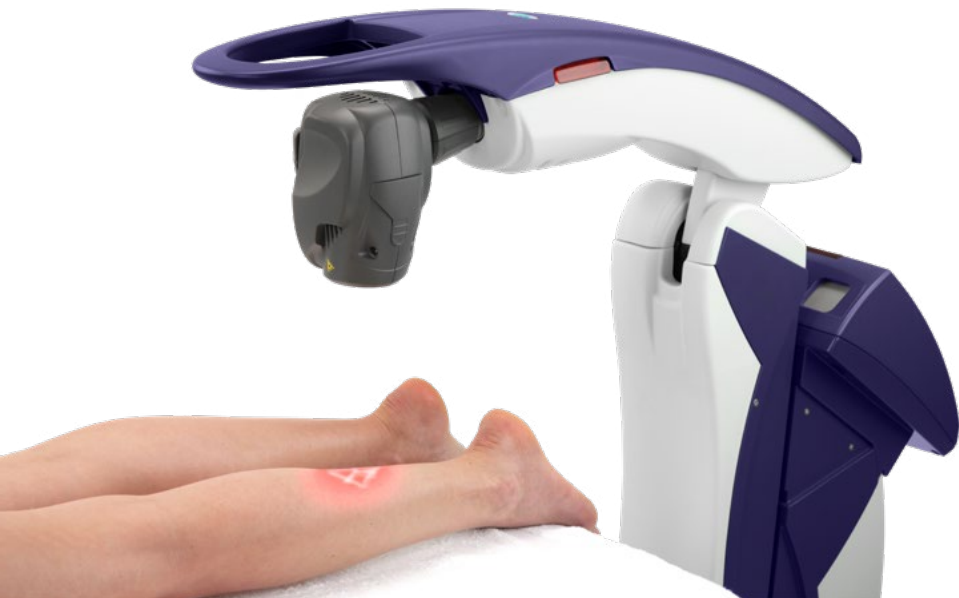Robotic lasers represent a transformative leap forward in light-based therapeutic technologies, offering enhanced efficacy, safety, and precision. With the ability to penetrate the tissue up to 5 centimeters while minimizing the risk of adverse effects, these trailblazing devices empower practitioners to deliver optimal care with unprecedented consistency and confidence.

# Key Indications for MLS<sup>®</sup> Laser Therapy

The innovative Multiwave Locked System<sup>®</sup> (MLS) Therapy Laser was developed in an effort to produce an efficient and simultaneous effect on pain, inflammation, and edema, exceeding the limitations of traditional low power therapy lasers while mitigating the risk associated with higher power devices.

The patented MLS pulse pattern precisely synchronizes 808nm and 905nm wavelength emissions to create energetic synergy that results in greater anti-inflammatory and analgesic effects than either emission can stimulate on its own, while minimizing the risk of thermal damage. It is this unique combination and synchronization of continuous and pulsed emissions that characterizes MLS and distinguishes it from other Class IV lasers.

Unlike early-generation Class IV technology, MLS Laser Therapy has the capability to deliver controlled laser energy. This unique feature provides more accurate therapeutic dose delivery, leading to consistent and repeatable results.



## ◆ Inflammatory Conditions

MLS Laser Therapy is effective in managing various inflammatory conditions, including tendonitis, neuritis, and osteoarthritis. By reducing inflammation, it alleviates pain and improves mobility.

## ◆ Pain Management

MLS Laser Therapy offers a non-pharmacological approach to pain management for acute and chronic conditions, providing relief without the potential side effects associated with medications.

## ◆ Bone Healing

MLS Laser Therapy research has shown promise in promoting bone regeneration. By enhancing cellular metabolism and facilitating the deposition of new bone tissue, it facilitates quicker recovery and reduces the risk of complications.

## ◆ Pre- and Post-Surgical Care

MLS Laser Therapy can be utilized to optimize surgical outcomes. Pre-surgical treatment helps prepare the body for the procedure by reducing inflammation and promoting tissue health, while post-surgical therapy accelerates healing, minimizes scar tissue formation, and enhances overall recovery.

## ◆ Wound Healing

By promoting angiogenesis, collagen synthesis, and epithelialization, MLS can expedite the healing process and reduce the risk of complications such as infection and chronic wounds.

In clinical practice, MLS Laser Therapy has demonstrated remarkable efficacy in addressing these indications, often yielding significant improvements in symptoms and functional outcomes. By harnessing the power of light energy, clinicians can offer patients a safe, non-invasive, and clinically proven modality for managing various musculoskeletal and soft tissue conditions.

# Understanding the Mechanism of Action of Photobiomodulation

In less than 15 minutes, a comprehensive treatment session targeting areas such as the neck or lower back can be completed using MLS Laser Therapy. But how does this remarkable therapy harness the power of light to induce therapeutic effects? Dr. Kasper delves into the fascinating realm of photons and their profound impact on the human body.

At the heart of photobiomodulation lies the principle of delivering photons—particles of light energy—into the body to trigger a cascade of biological responses. This process, akin to photosynthesis in plants, initiates an array of effects, including analgesia, anti-inflammation, and bio-stimulation. As photons interact with cellular components, they facilitate physiological changes that promote healing and alleviate symptoms.

While the intricacies of how light is processed within the body are extensively documented in scientific literature, Dr. Kasper emphasizes the clinical outcomes derived from these processes. Photobiomodulation has been shown to modulate histamine and cytokine levels, increase oxygenation, block pain receptors, release endorphins, boost ATP production, stimulate osteoblast activity, reduce scar tissue formation, enhance bone healing, and promote vascularization and nerve regeneration.

Yet, despite the remarkable recoveries witnessed in patients suffering from chronic conditions, Dr. Kasper's curiosity led her to explore further. She discovered a compelling link between photobiomodulation and stem cells—an intersection with profound implications for regenerative medicine.

Research indicates that photobiomodulation can enhance the proliferation and differentiation of mesenchymal stem cells, pivotal players in tissue repair and regeneration. By modulating cellular processes such as reactive oxygen species, ATP synthesis, and nitric oxide production, photobiomodulation sets off a chain reaction that promotes cell proliferation and initiates signaling cascades conducive to healing.

The implications are staggering, suggesting that photobiomodulation may have rejuvenating effects on aged bone marrow and mesenchymal stem cells, offering a potential avenue for cellular renewal and anti-aging interventions. These findings underscore the transformative potential of photobiomodulation therapy in enhancing the effectiveness of stem cell-based therapies, particularly in older individuals.


In essence, photobiomodulation emerges as a powerful tool not only for alleviating symptoms and promoting tissue healing but also for unlocking the regenerative potential of the body's own stem cells. Dr. Kasper's insights shed light on the profound implications of this therapy, offering hope for a future where cellular rejuvenation and healing are within reach.



# Photobiomodulation Research

Kile Kaspar, D.C. reviews the in vivo trials validating the effectiveness of the synchronized MLS Therapy Laser emission compared to untreated animals and animals treated with laser systems using the continuous 808nm and pulsed 905nm wavelength emissions independently and in a unsynchronized fashion.

Dr. Kaspar also includes a case report that opened her eyes to the treatment opportunities made possible by this innovative technology.





## In Vivo Research

# Nerve Regeneration

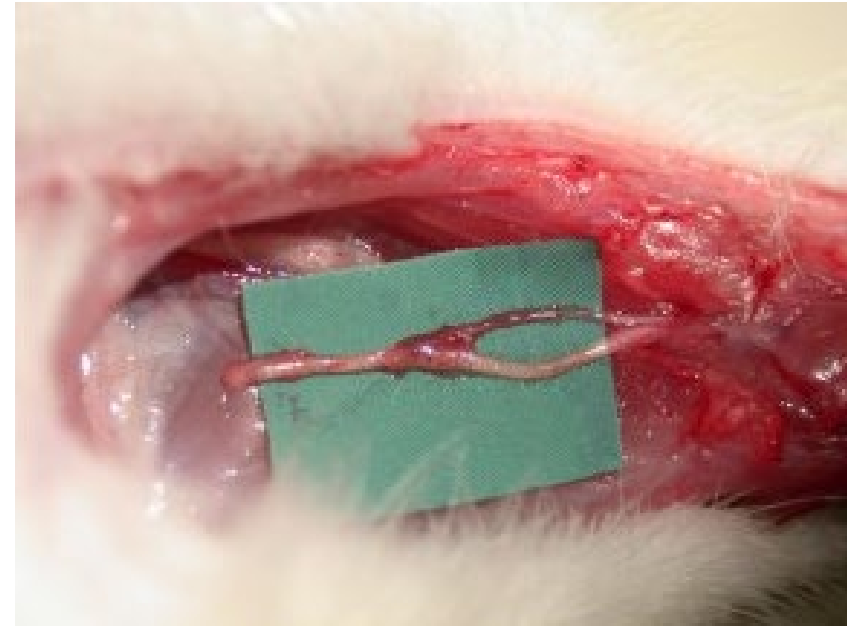In vivo trials were carried out on rats at the University of Turin in Italy, assessing the extent of nervous regeneration and the consequent muscle functions following lateral neurotomy (an operation that involves resecting the ulnar nerve from the median nerve and then rejoining them) after MLS Laser Therapy treatment.

Nerve regeneration was assessed by visual examination and transmission electronic microscopy. The nerve regeneration in animals treated with MLS Laser Therapy is extremely significant and can be seen in these photos; The median nerve in the treated animals was subject to optimal regeneration.

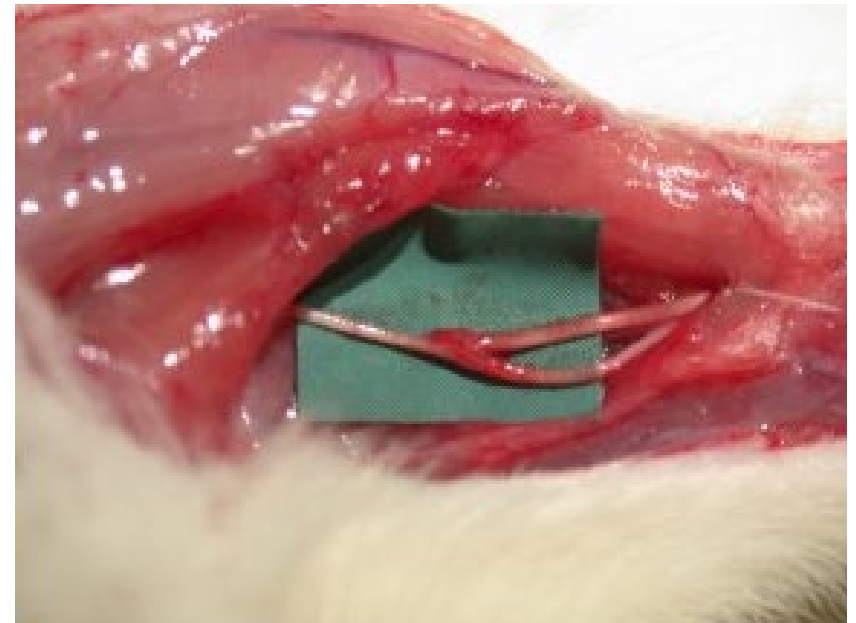Electronic microscopy confirmed the extent of nerve regeneration in animals treated with MLS. On a subcellular level, the restoration of organelles, mainly mitochondria, in the cells of treated animals was observed. Meanwhile, at the level of the nerve, re-myelination was evident. Finally, the number of nervous fibers regenerated shows how the recovery in treated animals was almost complete, while a smaller degree of stimulation is observed with the other therapy laser emissions tested in this trial.

The nervous regeneration and recovery of fiber myelination was followed by the restoration of the nerve's conduction capacity, and by the recovery of the innervated muscle contraction capacity, which returns to receiving the nervous stimulus correctly again. In fact, in untreated animals the innervated muscle becomes atrophic because it is not stimulated to contract correctly, while in treated animals it recovers its trophic factor.

## Control, Untreated Nerve



## Nerve Treated with MLS Laser Therapy



## In Vivo Research

# Muscle Recovery

In correspondence to the greater nerve regeneration obtained thanks to MLS Laser Therapy, the recovery of muscle mass in animals treated with this kind of stimulus is complete, a result which even amazed the researchers who carried out this trial.

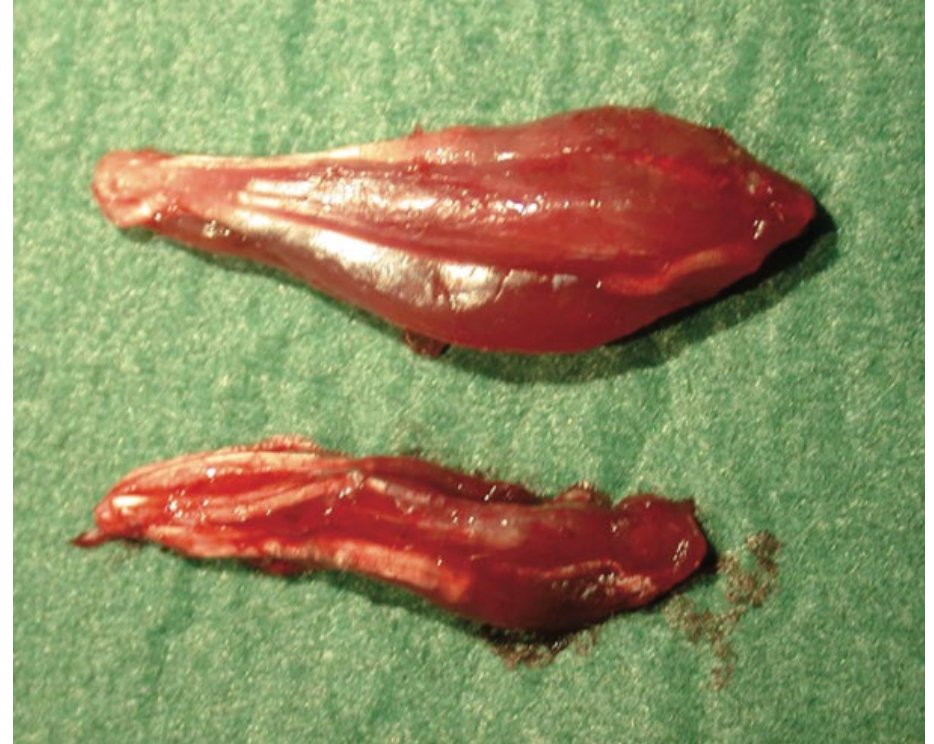The consequence of the complete muscular mass recovery and the almost total innervation recovery in animals treated with the MLS Laser emission is reflected in the greater muscular function recovery, assessed using the grasping test.

In order to assess the muscle's contractile capacity, an increasing weight was fastened to the foot of the animal that had undergone the nerve resection and was then treated with the laser. The muscle of treated animals regained a considerable contractile capacity, unlike that of the control group and animals treated with other types of therapy laser emissions.

These results demonstrate a very important fact: the MLS emission represents a stimulus that the cell perceives as 'different' from the other non-synchronized therapy laser emissions tested in this trial. In other terms, the synchronized MLS emission is a biologically 'new' stimulus that is able to induce a characteristic effect, which cannot be obtained when the 808nm and 905nm emissions are used separately. The combined emission provides dose-independent and stable biostimulation.

The results also confirm the extreme effectiveness of the MLS pulse in transferring energy to cells and tissues in an optimal fashion, where 'optimal' means an energy transfer able to elicit the maximum biological response.

**Muscle Treated with MLS Laser Therapy** (Top)



**Control, Untreated Muscle** (Bottom)

[Read the Full MLS Laser Therapy Scientific Report](#)

## Case Report

# Regression of Cervical Radiculopathy After Laser Treatment

Energy for Health, 17

**E. Perez, J.A. Natera, LD. Guzmán Hernández, J. Olalde**

Centro Médico Adaptógeno, Calle Dr. Santiago Veve & Calle Marti #1, Bayamón, PR 00961, Estados Unidos

A 46-year-old female patient was diagnosed with discogenic disease affecting multiple cervical discs, resulting in a narrowed spinal cord by 50%. Over the course of eight consecutive days of treatment, significant improvements were observed, particularly in the reduction of disc bulges at the affected levels.

Two months apart, MRI images showed remarkable changes: the spinal cord space was restored by 90%, and the disc bulge at one level was nearly eliminated. This visual evidence highlighted the effectiveness of MLS Laser Therapy in promoting tissue healing and alleviating symptoms.

The case study underscores the transformative potential of laser therapy in treating cervical radiculopathy, offering a non-invasive alternative to surgical interventions.

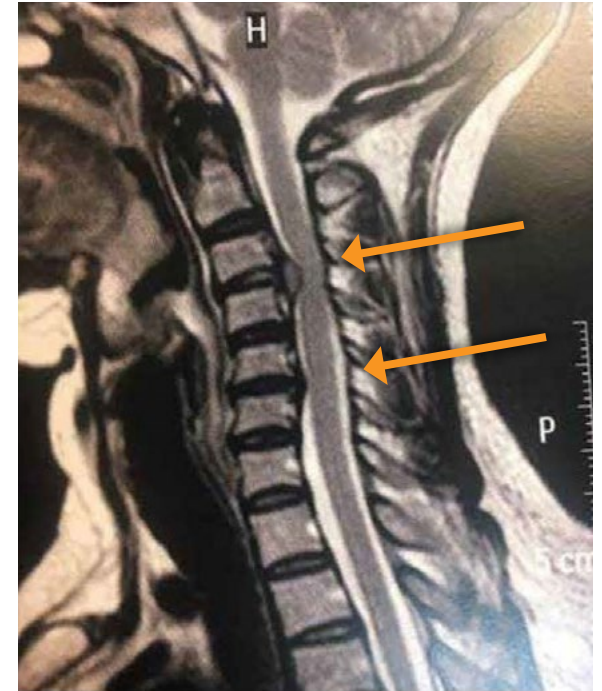
[Read the Full Case Report](#)

### Sagittal MRI Pre-Treatment

C3-4 disc bulge

50% narrow  
spinal cord

C5 spinal cord  
impinged

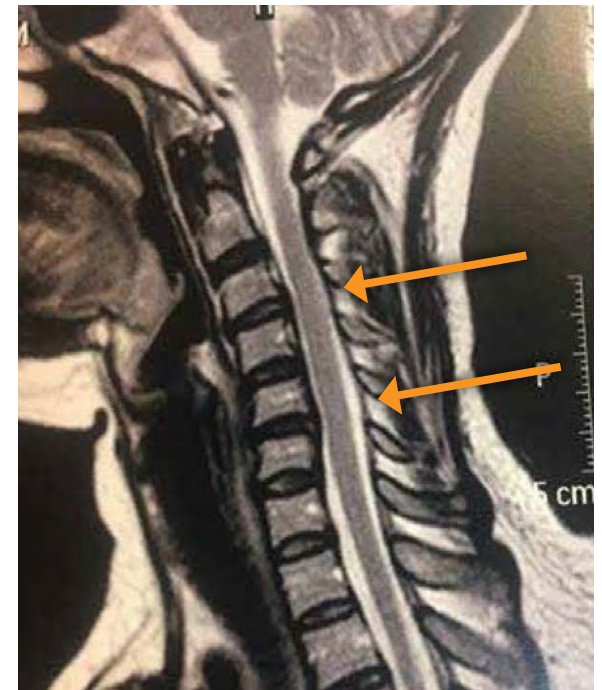

### Sagittal MRI After MLS Treatment

2 Months Later

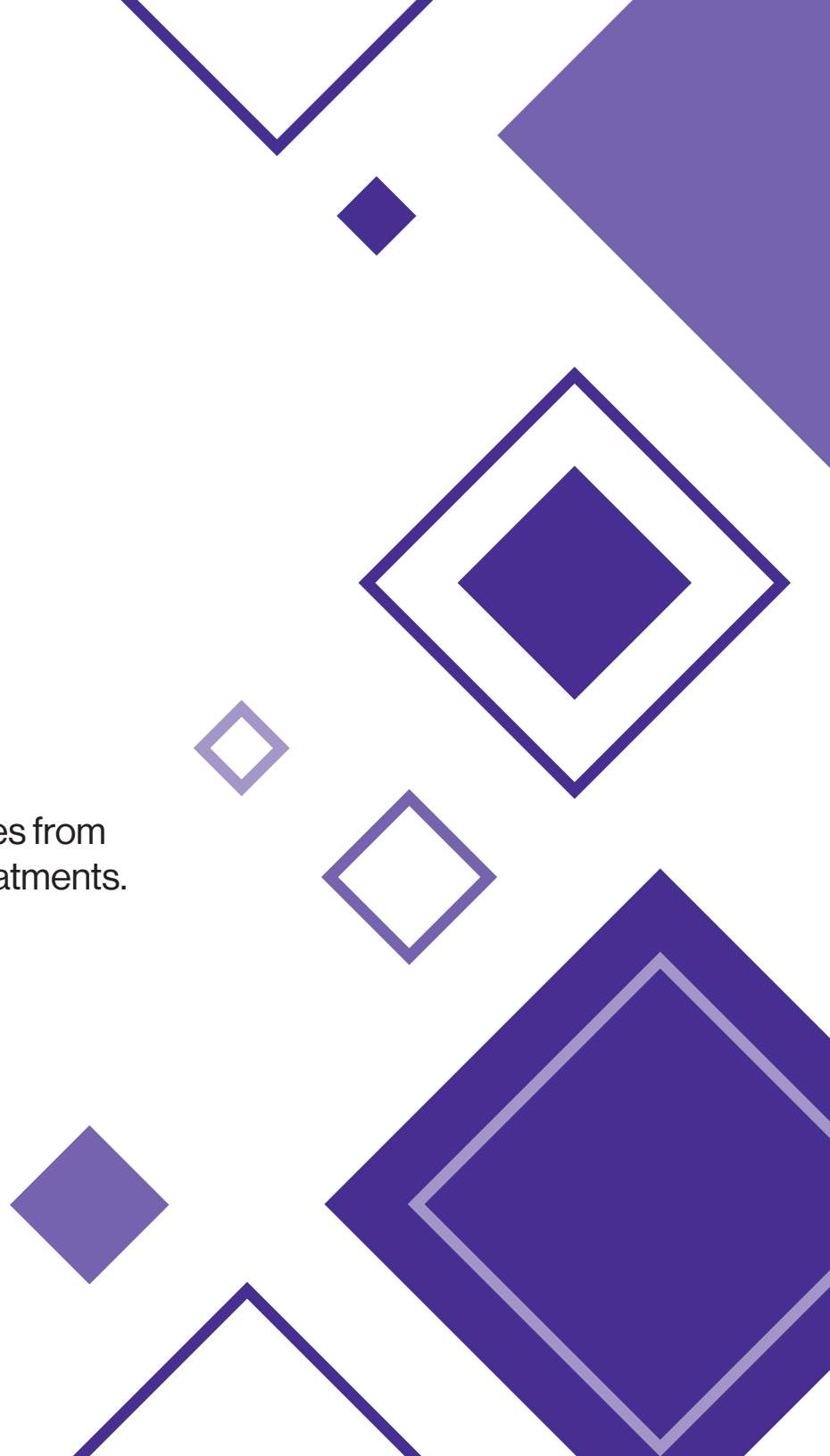Regression of herniated  
disc with 90% restitution  
of the spinal cord space

Disc bulge at C5 is  
almost completely gone



# Case Studies

Kile Kaspar, D.C. reviews MLS Laser Therapy case studies from her practice, including her personal journey receiving treatments.



## Case Study #1

# Dr. Kaspar's Recovery

**48-year-old female with a history of traumatic brain injury (TBI), pons, spinal cord, and cervical disc injury resulting from accelerated blunt force head trauma.**

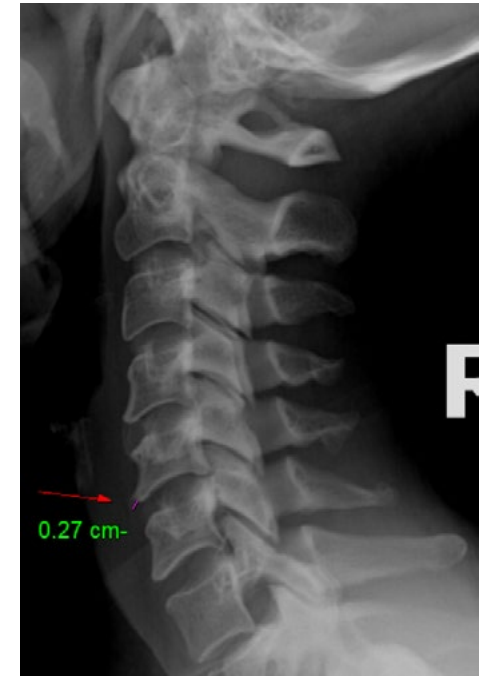Over the course of 13 years, Dr. Kaspar underwent various treatments including chiropractic care, active release technique, physical therapy, electrical muscular stimulation, ultrasound, laser therapy, acupuncture, and nutrition interventions.

Comparing X-rays taken in 2010 and 2023, remarkable improvements were observed. Despite some progression of vertebral arthritis, she maintained her cervical curve and disc spaces, with minimal changes in bone spur measurements. Notably, the patient experienced complete relief from symptoms such as clunking in the upper cervical complex, rapid heart rate episodes, numbness, and paralysis.

X-rays revealed stabilization of the alar and posterior ligaments (see [page 14](#)), preventing vertebrae from shifting onto the spinal cord and brain stem. In 2010, significant shifting was observed at C2-C5, which aligned perfectly by 2023. This alignment, coupled with improved George's line, signifies the cessation of symptoms associated with the patient's mode of injury (see [page 17](#)).

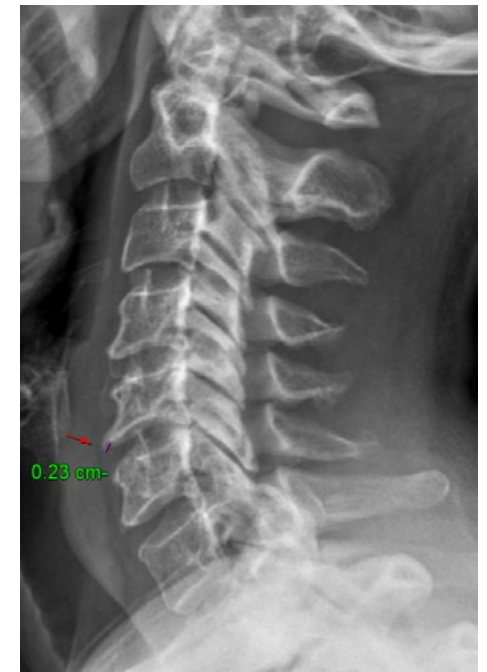Overall, the case study highlights the efficacy of comprehensive treatment, including MLS Laser Therapy, in promoting spinal stability, alleviating symptoms, and improving quality of life for patients with complex cervical injuries resulting from trauma.

[Watch the Video](#)



**X-Ray from 2010**

0.27 cm bone spur



**X-Ray from 2023**

At 0.23 cm, the bone spur did not progress in 13 years.

Maintained cervical curve.

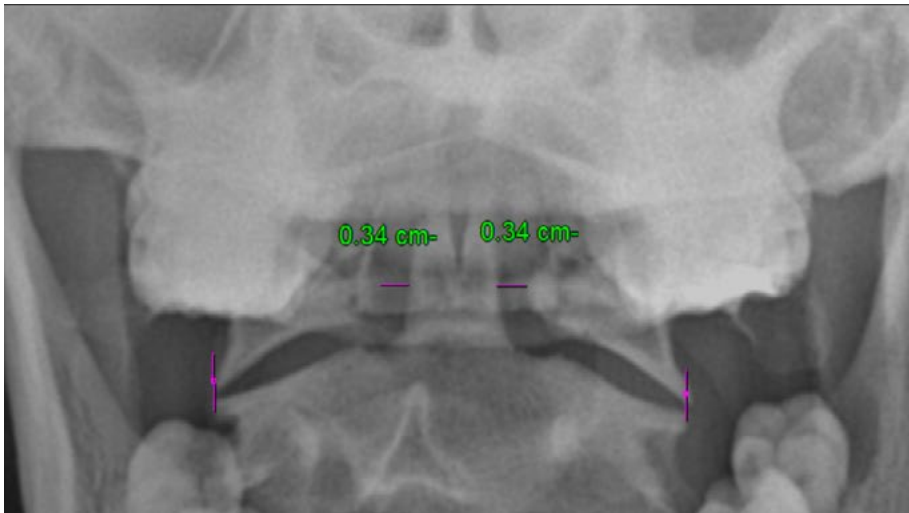
Disc spaces are maintained despite mild vertebral arthritis.

## Case Study #1

# Dr. Kaspar's Recovery

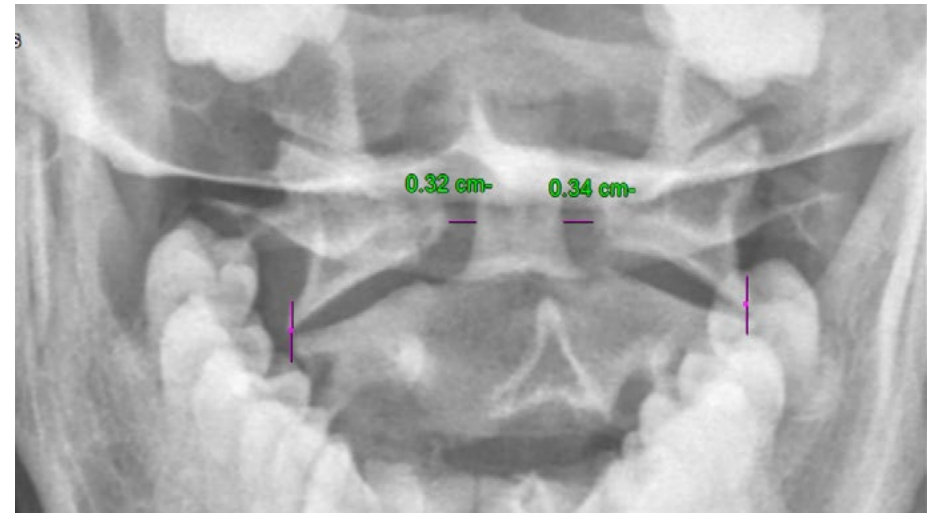
### X-Ray from 2010

Clunking in upper cervical complex associated with episodes of rapid onset heartrate between 160 and 180 BPM, facial numbness, numbness throughout the right side of the body mimicking a stroke, weakness or paralysis in both arms, digestive issues, difficulty swallowing, headaches, difficulty breaking, and, in severe episodes, loss of function in the entire body.



### X-Ray from 2023

Alar ligament x-rays show no progression in 13 years.



## Case Study #1

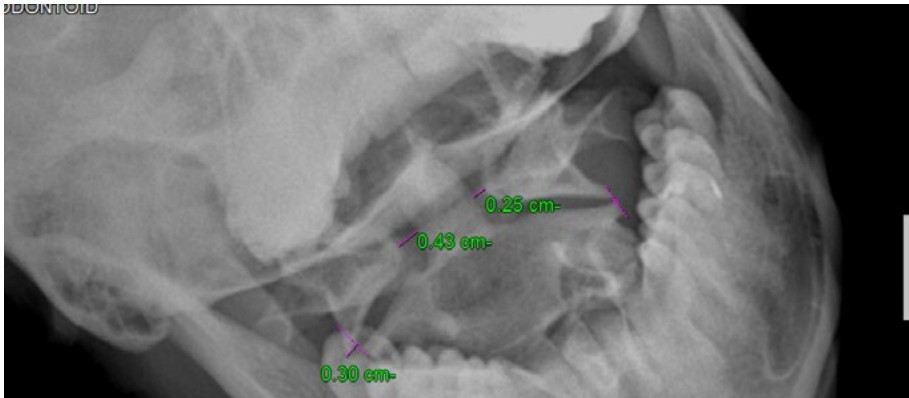
# Dr. Kaspar's Recovery

### X-Ray from 2010

When laterally bending to the left, see that the Odontoid is much closer to C1.

C1 shifting.


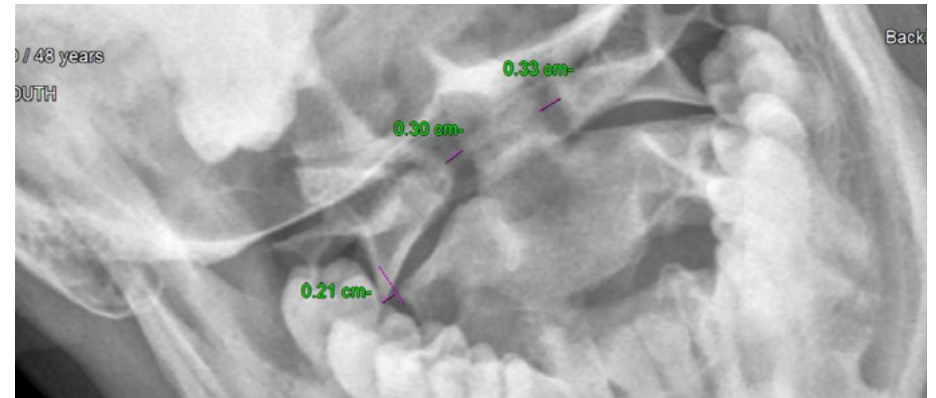
Lateral overhand of C1.



### X-Ray from 2023

Stabilized around the Odontoid on C1 and C2.

Much less overhand.




## Case Study #1

# Dr. Kaspar's Recovery

### X-Ray from 2010

Significant shifting of C1 and C2.

Right lateral overhang.


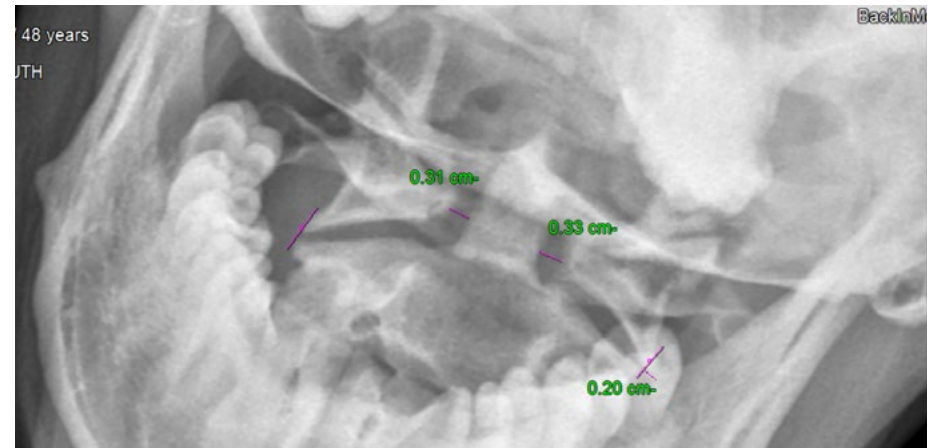


### X-Ray from 2023

C1 and C2 have stabilized

Less than half of the overhang seen in 2010

"This is significant because I don't have any of those symptoms anymore," Dr. Kaspar shared as she presented this case.



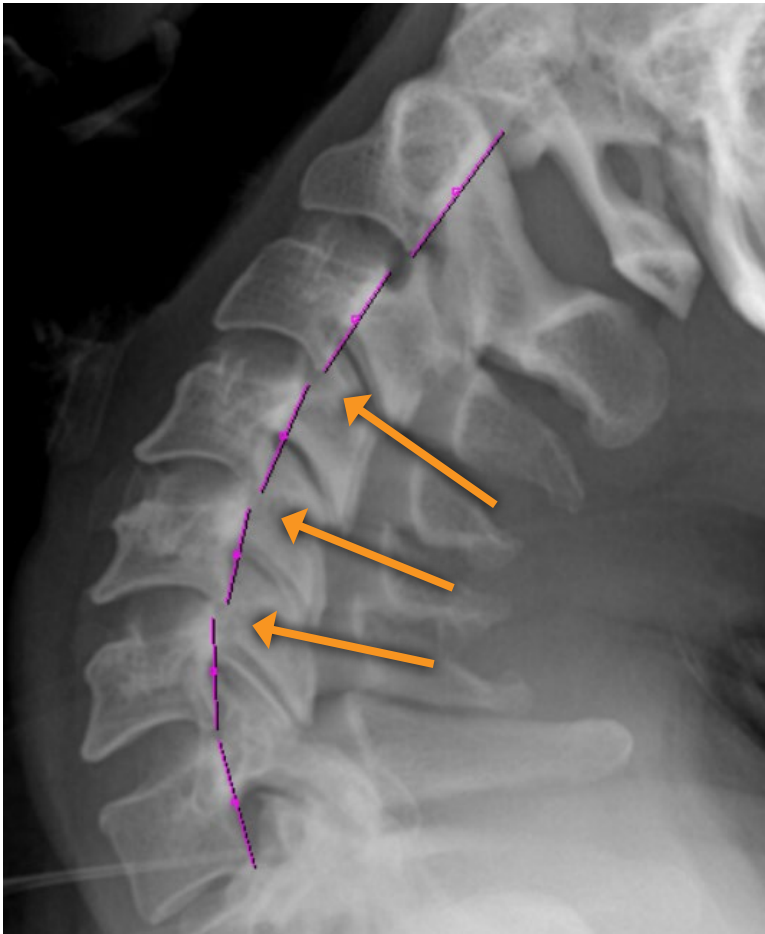


## Case Study #1

# Dr. Kaspar's Recovery

### X-Ray from 2010

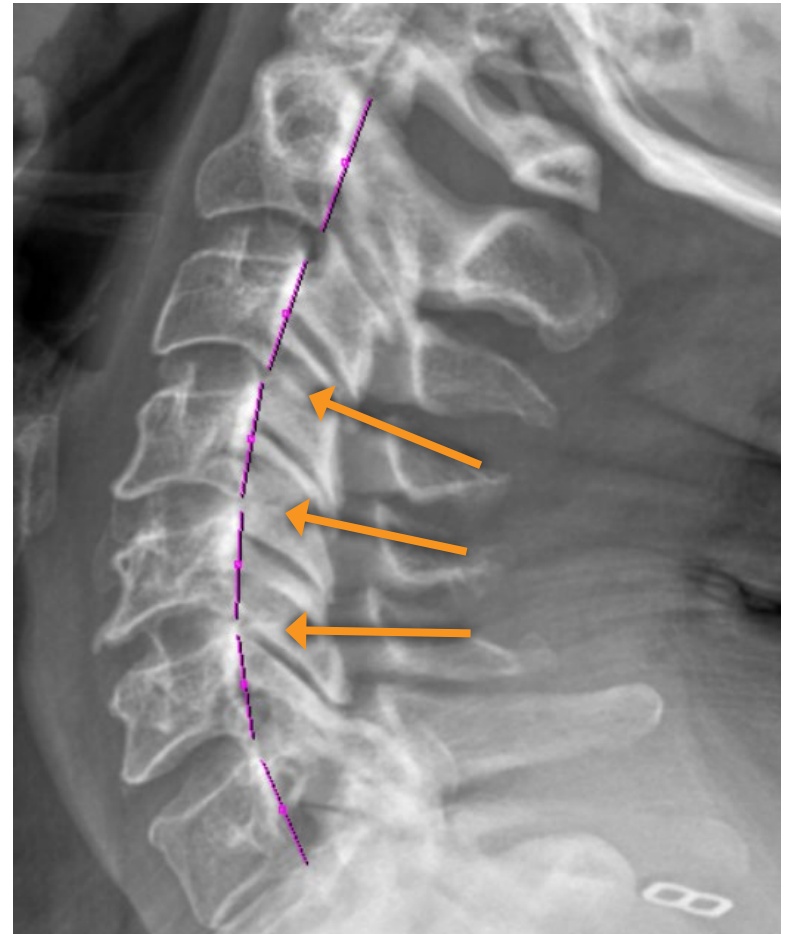
In extension, stair stepping is visible at C2, C3, C4, and C5, straightening back at C6.



### X-Ray from 2023

Improvement in George's line.

"With the combination of the alar and the posterior ligament healing, this has stopped my vertebrae from shifting onto my spinal cord and brain stem, alleviating every symptom I ever had."

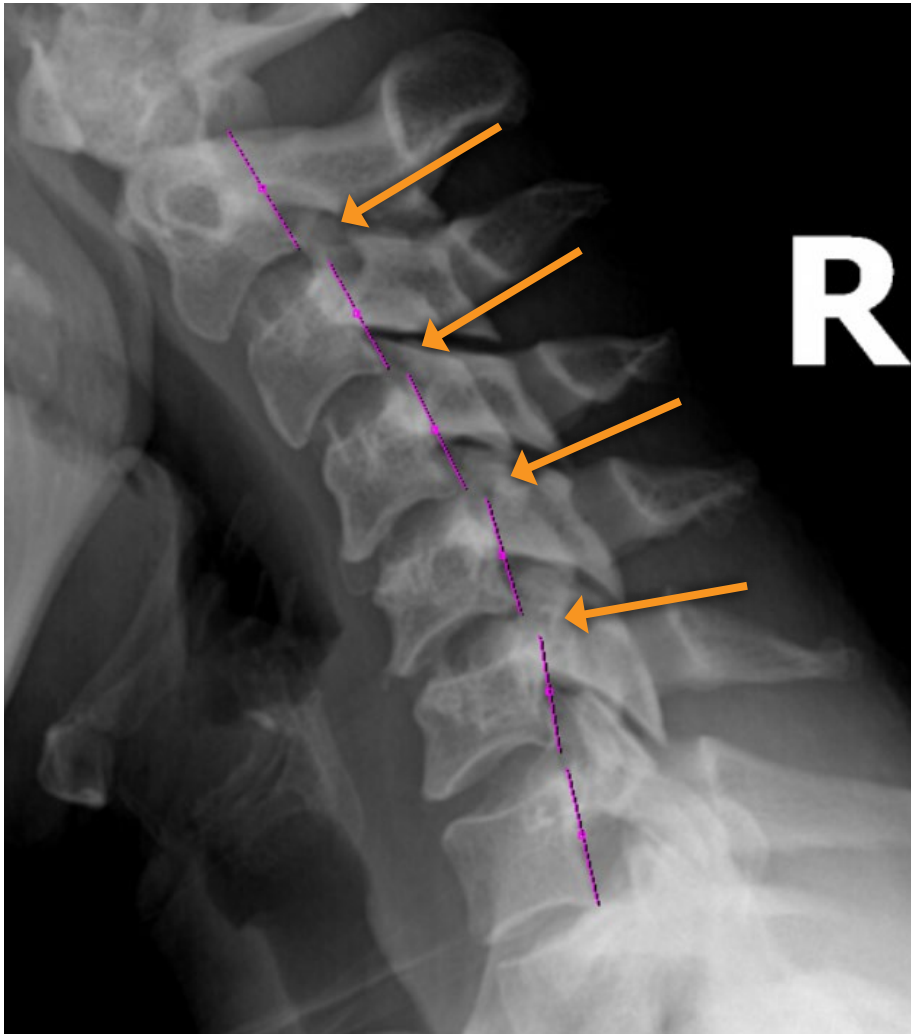


## Case Study #1

# Dr. Kaspar's Recovery

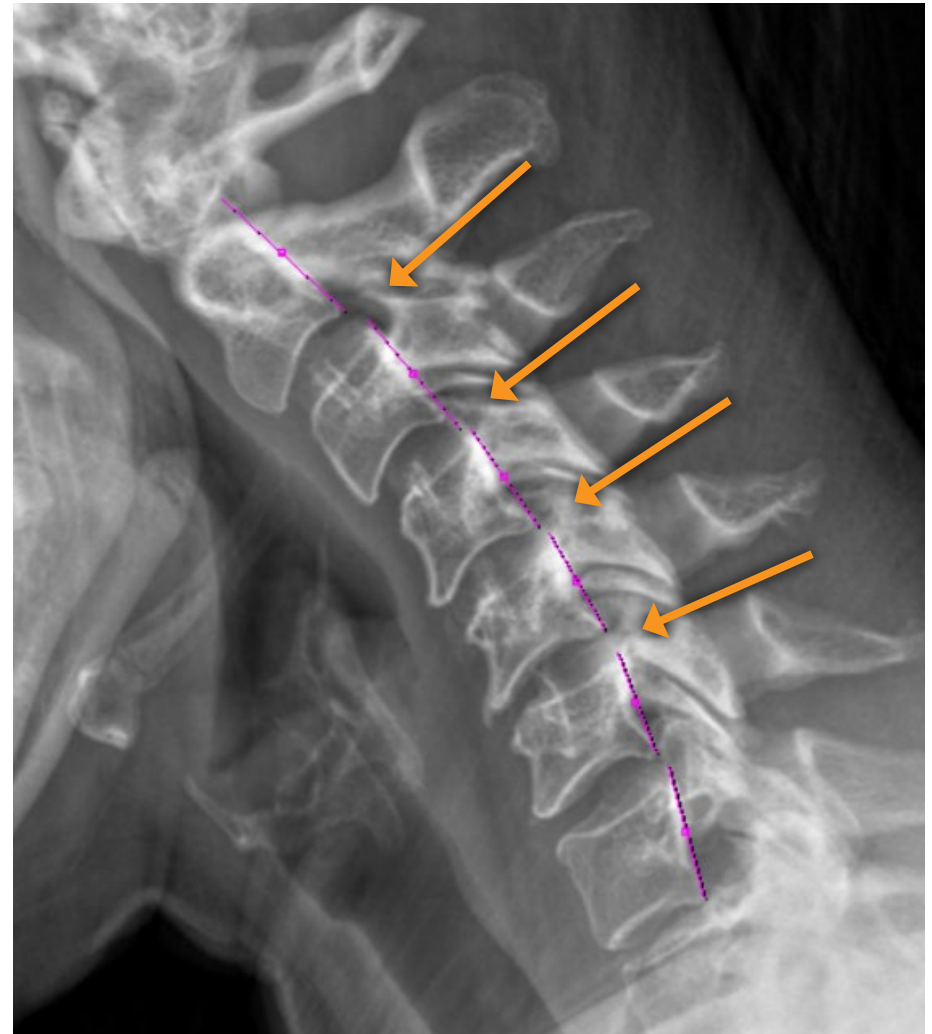
### X-Ray from 2010

In inflexion (the mode of her injury) there is significant shifting in C2, C3, C4 and C5, straightening back at C6.



### X-Ray from 2023

The spine is perfectly aligned.



## Case Study #2

# Whiplash/Cervical Fracture

**84-year-old female with a history of whiplash injury (decades prior) and prolonged medication use.**

An 84-year-old female with a history of whiplash injury and prolonged medication use found herself slumped over in a wheelchair. Due to the progression of her condition, she was unable to hold her head up.

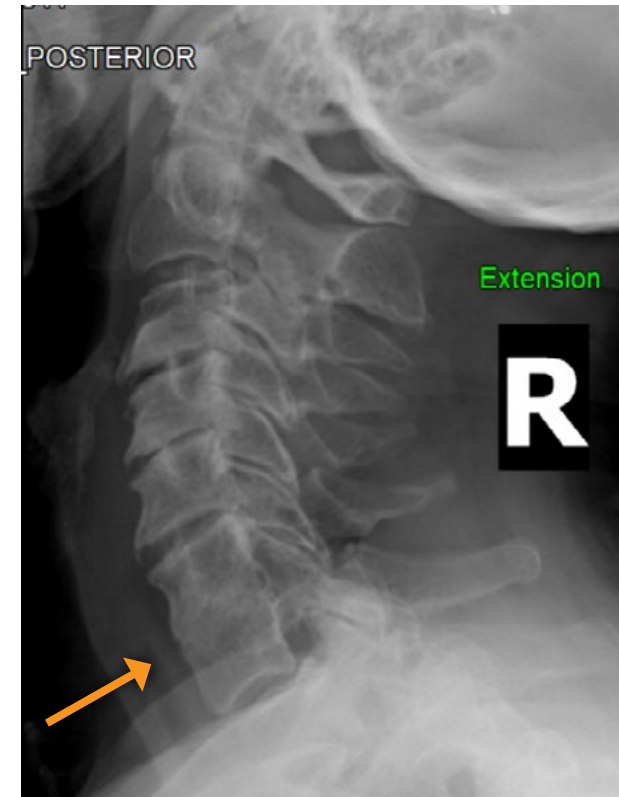
Dr. Kaspar admits that chiropractic care would have little effect on this patient's quality of life. However, her practice has seen good results using laser therapy to decrease muscle spasms and pain.

Dr. Kaspar recommended a treatment plan of 24 laser therapy sessions. Within a week of treatment, her symptoms began to alleviate and within a month she was out of her wheelchair. Six months later she was walking normally showcasing the transformative impact of laser therapy on her quality of life.

A five view cervical series, including flexion and extension lateral views, with a repeat open mouth view, has been submitted for examination. There is partial fusion of C6 and C7. Patient history is needed to determine if this is due to surgical fusion or if this is degenerative in nature. There are no obvious findings of compression fractures. The spinous processes are intact. The atlantodental interval is normal. There is between 75 and 80% loss of disc space height at C3-C4 and C4-C5, with slightly less disc degeneration at C5-C6. Osteophytes are present from C3 through C6. There is articular pillar degeneration at most cervical levels. Uncinate process hypertrophy is present at C4 through C7. The cervical spine is hypolordotic. There is mild retrolisthesis of C4 on C5. Overall range of lumbar motion is adequate. There is restricted intersegmental mobility at most levels during flexion. There are no findings of instability during motion.

### IMPRESSIONS:

1. Partial fusion of C6 and C7. As indicated above, history is needed to determine if this is due to surgical intervention or advanced degenerative changes.
2. Advanced discogenic spondylosis at C3-C4, C4-C5 and C5-C6.
3. Multilevel articular pillar degeneration and Luschka hypertrophy that may produce intervertebral foraminal or central canal stenosis. Hypolordotic cervical spine with adequate range of motion.
4. Retrolisthesis of C4 and, to a lesser extent, C3, which is stable during motion.
5. Intersegmental hypomobility at most levels during flexion.



### Extension X-Ray

Blocked vertebra.

Partial fusion of C6 and C7.

No movement throughout the cervical spine.

[Watch the Video](#)

## Case Study #3

# Supraspinatus Tear

## 52-year-old female tennis player finds alternative to shoulder reconstruction surgery.

A 52-year-old female underwent right shoulder reconstruction surgery and was scheduled for surgery on her left shoulder. However, due to a difficult recovery from her first surgery, she began exploring conservative care options.

Skeptical about the efficacy of laser therapy, she reluctantly sought treatment as per her friend's recommendation. Despite significant MRI findings and initial doubts, she experienced a remarkable recovery after just 12 visits. One month later, she was back on the tennis court preparing for an upcoming tournament.


She is now an advocate for chiropractic care and laser therapy, and has become Dr. Kaspar's largest referral source for laser patients.

A five view cervical series, including flexion and extension lateral views, with a repeat open mouth view, has been submitted for examination. There is partial fusion of C6 and C7. Patient history is needed to determine if this is due to surgical fusion or if this is degenerative in nature. There are no obvious findings of compression fractures. The spinous processes are intact. The atlantodental interval is normal. There is between 75 and 80% loss of disc space height at C3-C4 and C4-C5, with slightly less disc degeneration at C5-C6. Osteophytes are present from C3 through C6. There is articular pillar degeneration at most cervical levels. Uncinate process hypertrophy is present at C4 through C7. The cervical spine is hypolordotic. There is mild retrolisthesis of C4 on C5. Overall range of lumbar motion is adequate. There is restricted intersegmental mobility at most levels during flexion. There are no findings of instability during motion.

### IMPRESSIONS:

1. Partial fusion of C6 and C7. As indicated above, history is needed to determine if this is due to surgical intervention or advanced degenerative changes.
2. Advanced discogenic spondylosis at C3-C4, C4-C5 and C5-C6.
3. Multilevel articular pillar degeneration and Luschka hypertrophy that may produce intervertebral foraminal or central canal stenosis. Hypolordotic cervical spine with adequate range of motion.
4. Retrolisthesis of C4 and, to a lesser extent, C3, which is stable during motion.
5. Intersegmental hypomobility at most levels during flexion.

Watch the Video



## Case Study #4

# Traumatic Brain Injury

## 11-year-old male with multiple traumatic brain injuries, concussions, and neck injury.

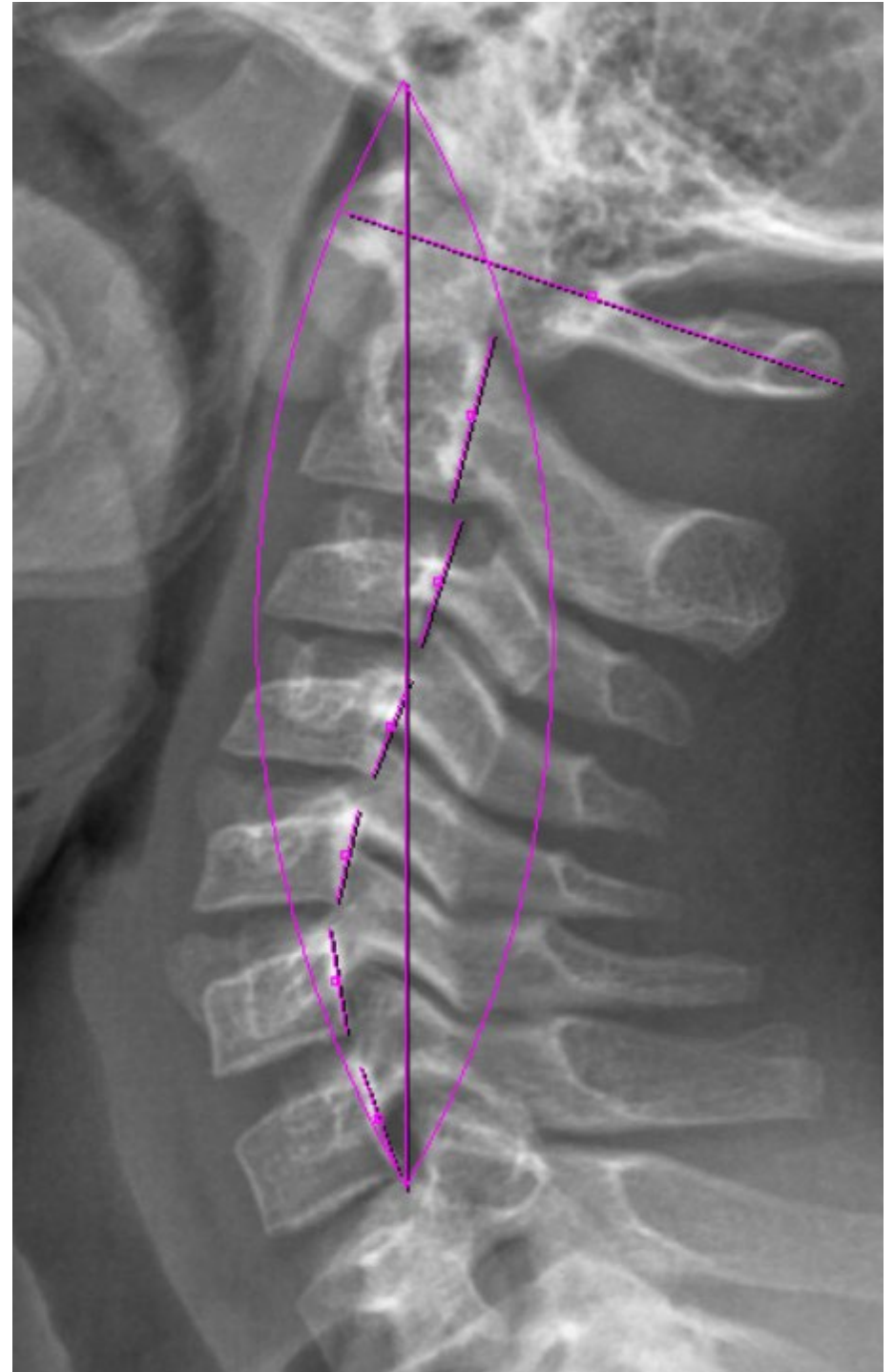
An 11-year-old male with a history of three traumatic brain injuries and three concussions, leading to a myriad of symptoms including headaches, difficulty sleeping, difficulty breathing, increased heartrate, numbness and tingling, digestive issues, and others. Despite numerous doctor visits, prescriptions, and various treatments and therapies, including chiropractic and nutritional interventions, his condition continued to deteriorate.

Upon examination, it was discovered that the patient had wedging at C5 and C4 with a break in George's line observed on X-rays. Flexion-extension x-rays (see [page 22](#)) further revealed increased translation of C1 and C2, along with retroflexion of C4 on C5 and C5 on C6. The radiology report confirmed these findings (see [page 23](#)).

Within 78 hours of the first MLS Laser Therapy treatment session, he reported significant relief from headaches, improved sleep quality, regulated breathing, and reduced heart rate. Over subsequent sessions, his symptoms continued to improve, with the exception of some residual hand numbness and tingling.

This case study underscores the efficacy of laser therapy in addressing underlying cervical spine issues and alleviating symptoms associated with traumatic brain injuries. The rapid and substantial improvements observed highlight the potential of laser therapy as a non-invasive and effective treatment modality for pediatric patients with complex neurological conditions.

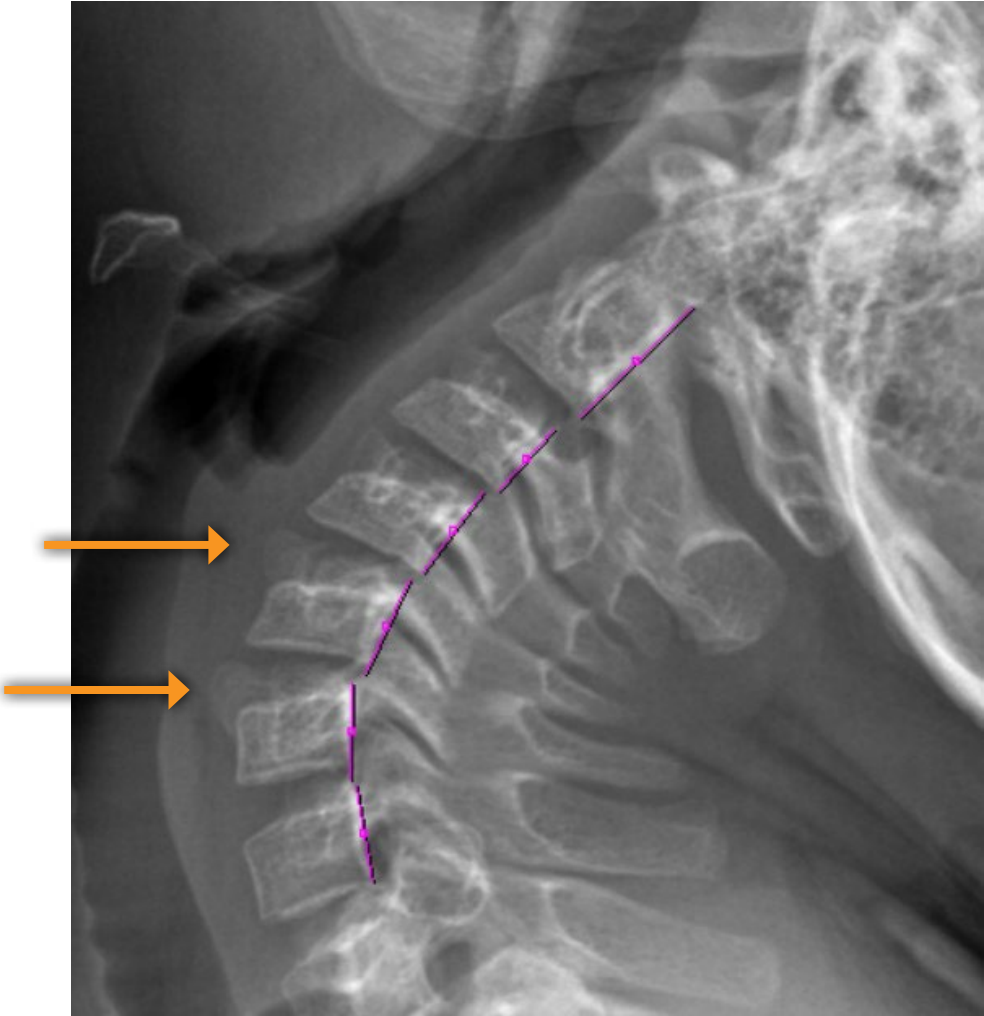
[Watch the Video](#)



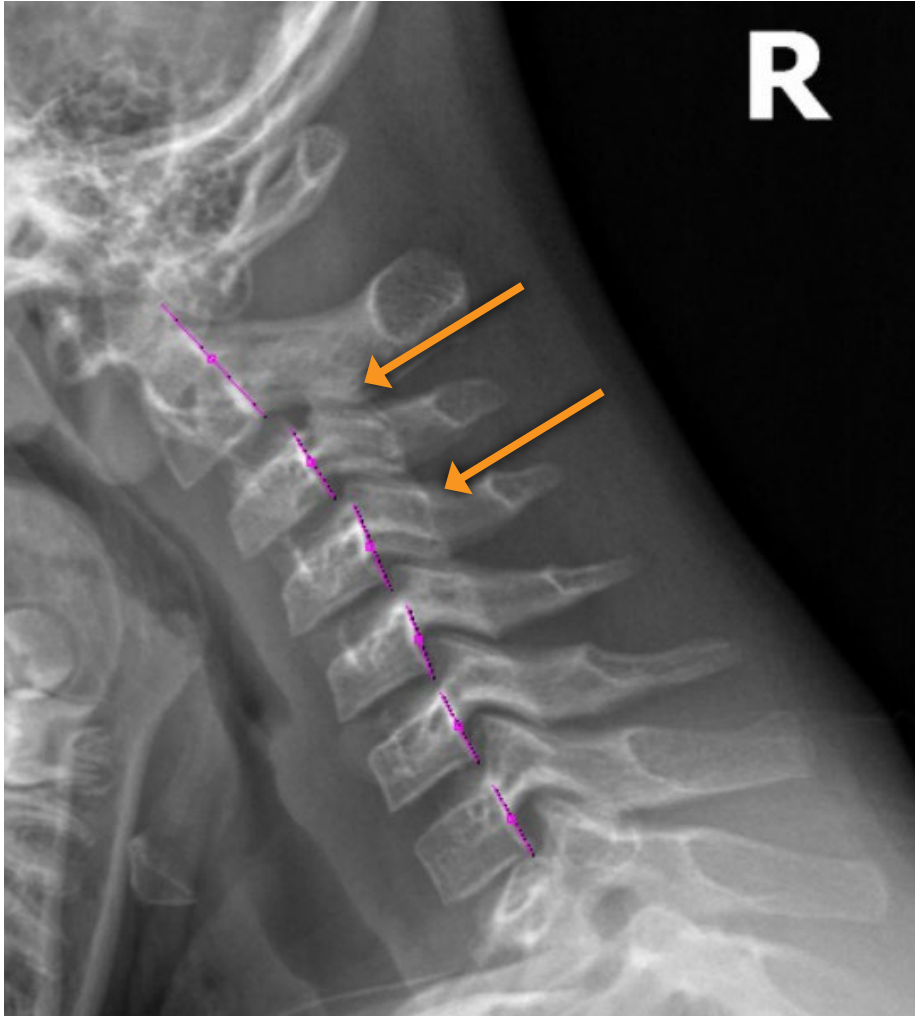
Case Study #4

# Traumatic Brain Injury

Extension X-Ray



Flexion X-Ray



## Case Study #4

# Traumatic Brain Injury

### Radiology Report

**History:** HX OF CONCUSSIONS

**Procedure:** AP, lateral, AP open mouth and oblique views of the cervical spine are supplemented with flexion and extension views.

**Findings:**

CERVICAL SPINE: Seven views of the cervical spine, including flexion and extension, as well as right and left lateral bending open mouth views, have been submitted for evaluation. The atlantodental interval is intact and stable during flexion and extension. There may be slight increased translation of C1 relative to C2 during right lateral bending, with only minimal overhang of the right lateral mass. The cervical vertebral bodies, discs and articular pillars are well formed. The upper cervical spine is hypolordotic, with overall range of motion being normal. There does not appear to be instability during flexion or extension. There is approximately 2 mm increased translation of C2 on C3 during flexion, which is not unusual for this age group. The neutral lateral view demonstrates mild retrolisthesis of C4 on C5 and C5 on C6 that does not increase during extension, but slightly reduces during flexion.

**Impression:**

1. Slight increased translation of C1 during right lateral bending, with mild increased translation of C2 during flexion.
2. Retrolisthesis of C4 on C5 and C5 on C6 on the neutral lateral view that slightly reduces during flexion.
3. Upper cervical hypolordosis with good range of motion.

## Case Study #5

# Sciatica

### 32-year-old female with severe low-back pain progressing to sciatica.

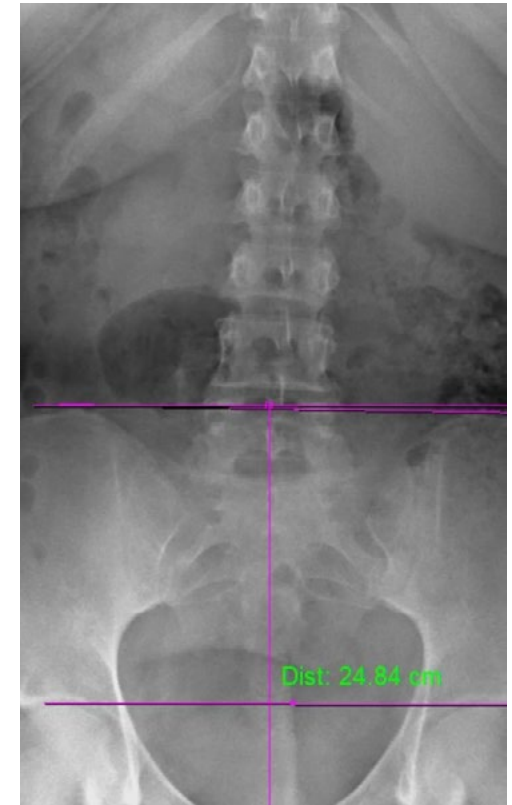
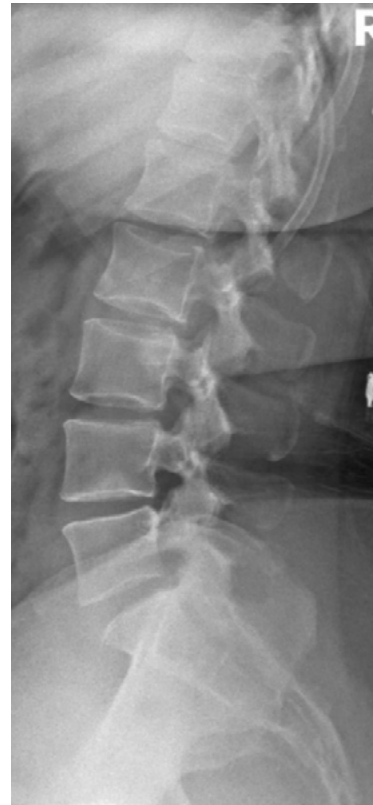A 32-year-old female presented with severe low back pain progressing to sciatica, experienced difficulty walking, weakness in lower limbs, and intermittent incapacitating pain. Despite making some progress after undergoing numerous treatments and therapies, including laser therapy, she experienced relapses, prompting further investigation.

X-rays (see [page 25](#)) and a radiology report (see [page 26](#)) revealed surprising findings, including a reverse cervical curve, translation at multiple cervical levels, and abnormalities indicative of spinal cord compression. This unexpected discovery shed light on the root cause of her symptoms, which had been overlooked.

Utilizing robotic MLS Laser technology, targeted treatment was administered to the affected areas, resulting in immediate relief and improved mobility. Within a couple of months, the patient became pain-free and was able to enjoy a vacation overseas without any low-back pain.

This case study underscores the importance of thorough assessment and personalized treatment approaches in addressing complex musculoskeletal conditions. The successful outcome highlights the transformative potential of laser therapy in relieving pain and restoring function, even in cases where traditional treatments have failed to provide lasting relief.

Dr. Kaspar also notes that this patient was initially anti-chiropractic, but sought treatment after a referral from a friend who was treated for sciatica with MLS Laser Therapy. In addition to the clinical benefits of laser therapy, this case highlights opportunities to tap into groups of patients who might not otherwise consider chiropractic care.



[Watch the Video](#)



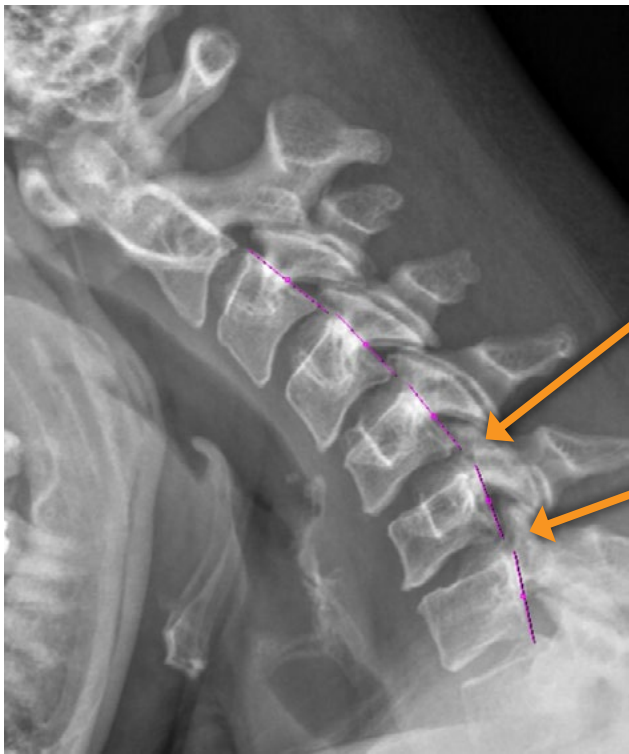# Case Study #5

## Sciatica

### Flexion

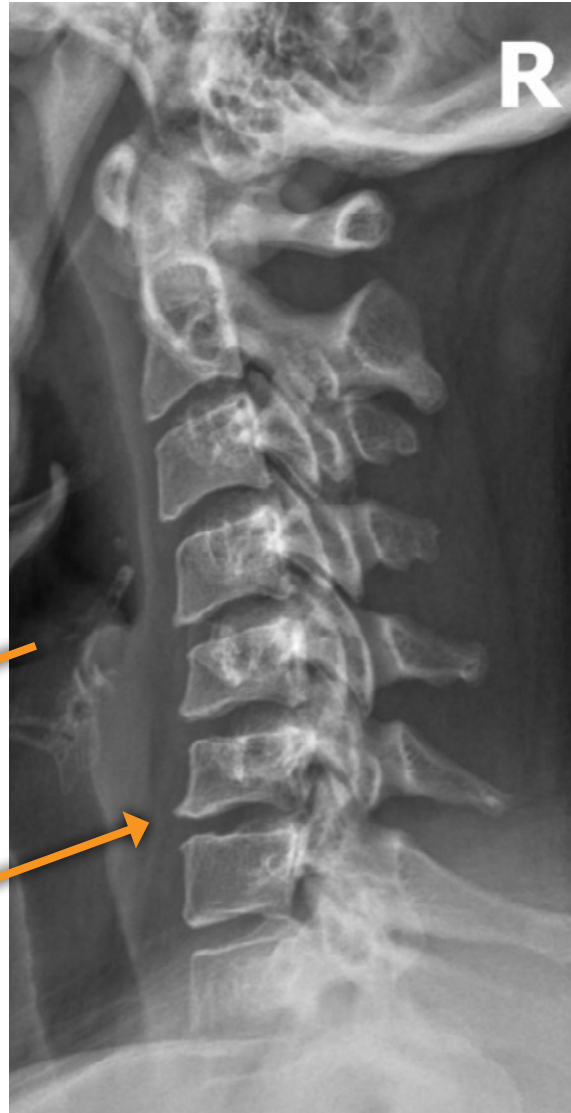Break at 5, 6 and 7

Gapping on backside, enclosing a wedge on the front side



Reverse Cervical Curve

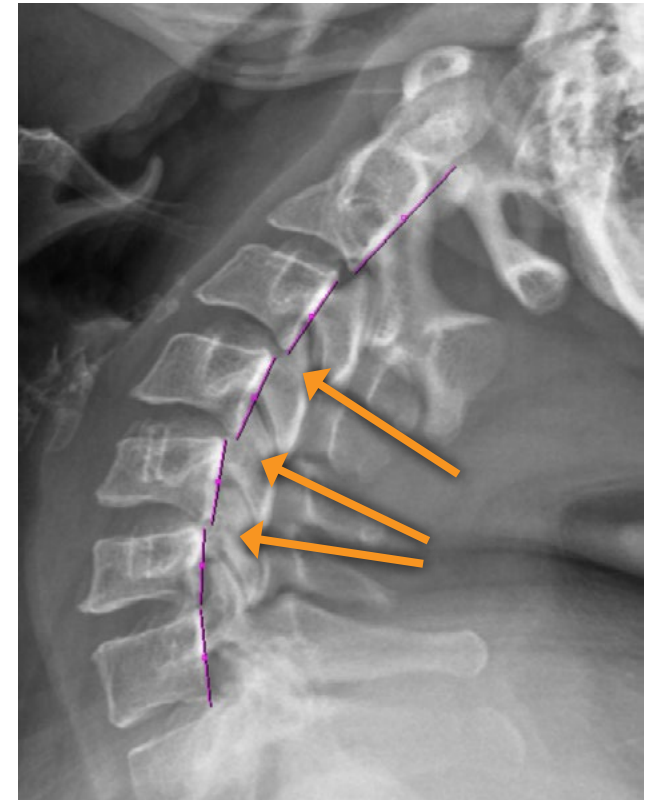
Bone spur developing



### Extension

Break at 3, 4, and 5, straightening back up at 6, 7

Translation



# Case Study #5

# Sciatica

## Radiology Report

**History:** NECK AND BACK PAIN

**Procedure:** 3 view cervical, 2 view thoracic and 2 view lumbar series are submitted.

**Findings:**

**CERVICAL SPINE:** A five view cervical series, including flexion and extension lateral views, has been submitted for examination. The atlantodental interval is stable during motion. There are no findings of vertebral body fractures or pathology. There is a small osteophyte along the inferior endplate of C6 and possibly C4. Obvious disc degeneration is not apparent. The cervical spine is hypolordotic with reverse of the lordosis that may be related to previous injuries. Range of flexion and extension is within normal limits. There is approximately 2 mm increased translation of C3 on C4 during extension, with lesser increased translation of C2 on C3 and C4 on C5.

**THORACIC SPINE:** AP and lateral views demonstrate 12 rib-bearing vertebrae, with the 12th ribs being hypoplastic. The vertebral body heights are maintained. There is very slight thinning of the T9-T10 disc anteriorly. This finding may be due to anomalous development; however, if previous injuries have occurred, there is a possibility of early disc degeneration. The thoracic spine is hypokyphotic. There are no findings of a significant scoliosis.

**LUMBAR SPINE:** AP and lateral views, with an AP pelvic view, have been provided for evaluation. The five lumbar vertebrae are well formed with normal density. There are no findings of a spondylolisthesis. Significant disc degeneration is not apparent. The lumbar spine is hypolordotic with posterior weight bearing. There is an area of increased density overlying the posterior superior corner of L3 on the lateral view that may represent superimposed structures. If this area is locally symptomatic, a spot lateral view should be obtained. The bony pelvis is intact, with the joints of the pelvis being normal.

**Impression:**

1. No radiographic findings that would contraindicate chiropractic care.
2. Reversed cervical lordosis with good range of motion.
3. Mild increased translation of C2, C3 and C4 during extension.
4. Hypokyphotic thoracic spine with lumbar hypolordosis and posterior weight bearing.
5. Slight disc thinning at T9-T10 that is due to either anomalous development or possibly previous injuries.

Thank you for choosing Midwest Radiology Consultants as your imaging specialist.

## Case Study #6

# Wound Healing

### 13-year-old male with Mowat-Wilson Syndrome faced complications after abdominal surgery.

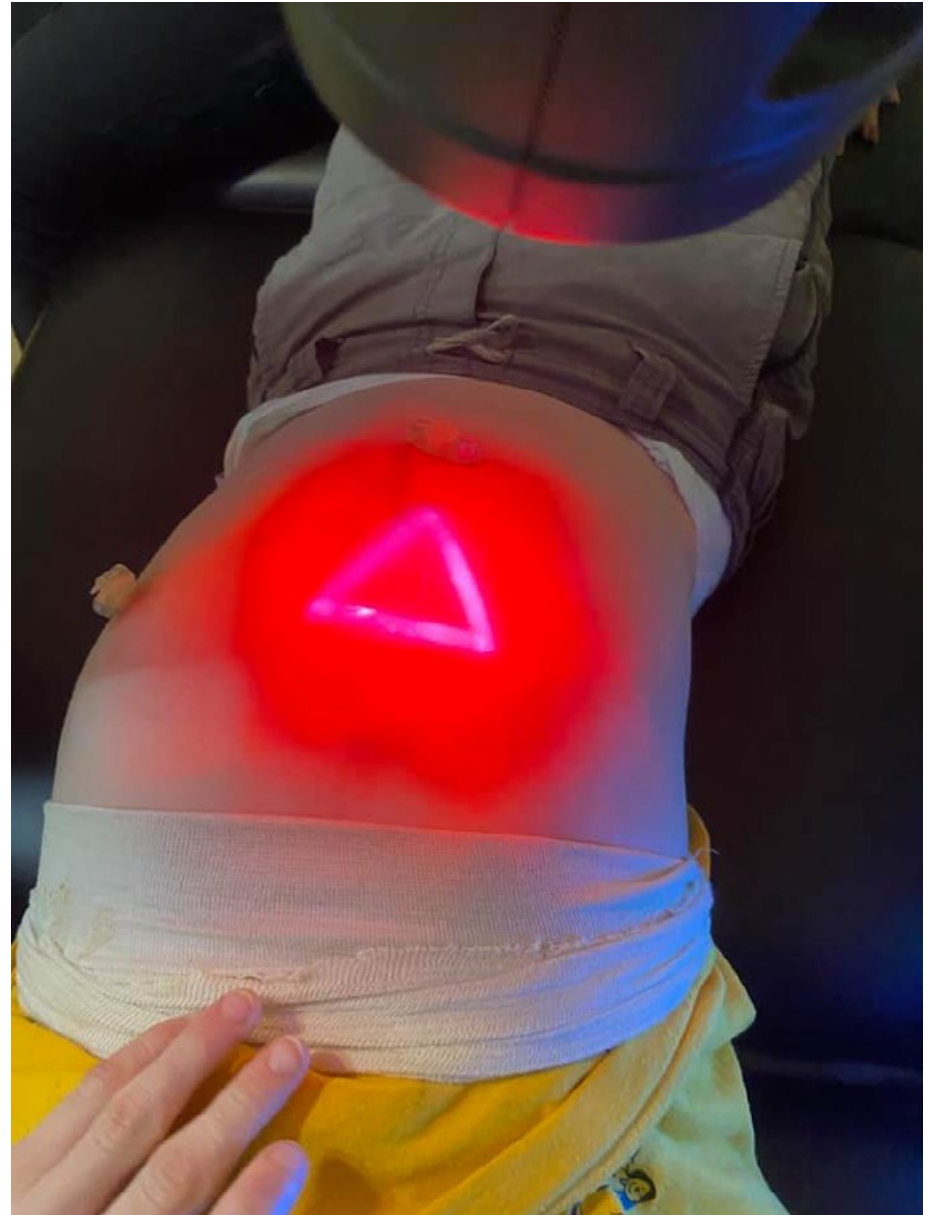
A 13-year-old male diagnosed with Mowat-Wilson Syndrome, a rare genetic condition, underwent abdominal surgery and face complications, including failed skin grafts and persistent infections. The patient's condition remained critical.

Seeking alternative options, the patient's mother brought him to receive laser therapy treatment. Within 24 hours of the first laser session, a significant reduction in inflammation was observed, followed by the breaking of fever within the first week. Over the course of two months, remarkable healing progress was made, with the wound closing completely (see [page 28](#)), much to the amazement of the home health nurse and medical professionals.

Months later, the patient returned to the clinic to receive laser therapy before hernia repair surgery. Pre-surgical laser treatments facilitated the healing process, leading to surprisingly healthy tissue and a smooth hernia repair surgery (see [page 29](#)). Despite encountering a post-surgical infection, prompt intervention and laser therapy ensured a speedy recovery.

This case study highlights the profound impact of laser therapy in promoting wound healing, reducing inflammation, and aiding in surgical recovery, offering hope and relief to patients and their families facing challenging medical conditions.

[Watch the Video](#)

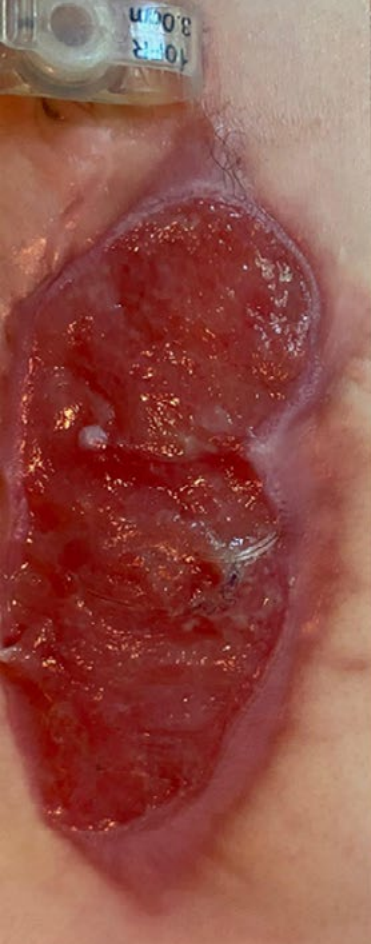

# Case Study #6

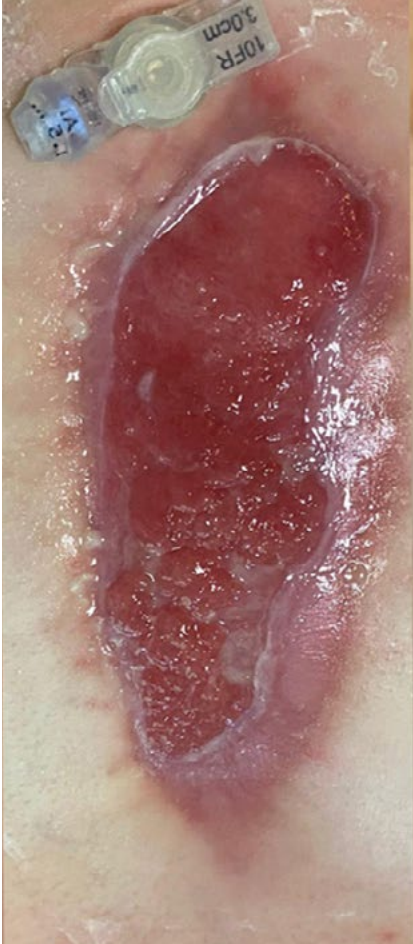# Wound Healing

Over the span of 5 weeks, the patient's wound decreased from 9cm x 2.5cm to 2cm x 1cm.

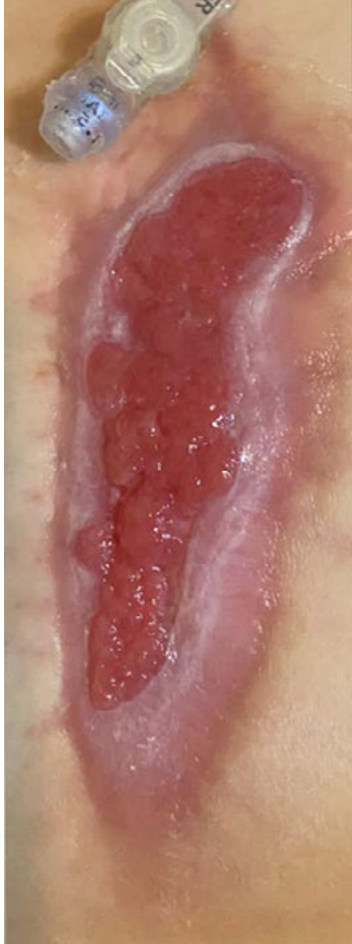**8/15/2021**  
**Pre-treatment**



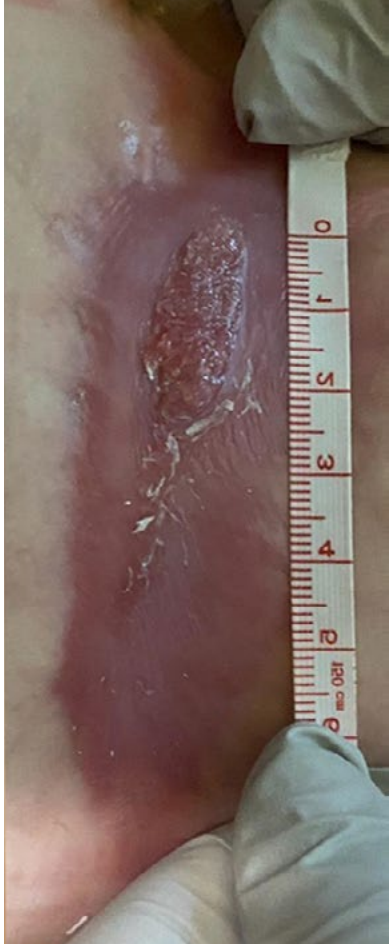
**8/22/2021**  
**1 week**



**8/31/2021**  
**2 weeks**



**9/23/2021**  
**5 weeks**

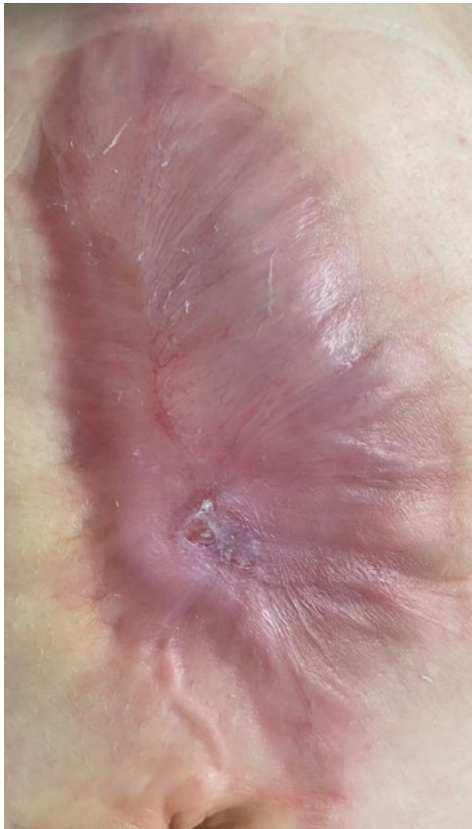

## Case Study #6

# Wound Healing

10/22/21

After two months, the wound completely closed.

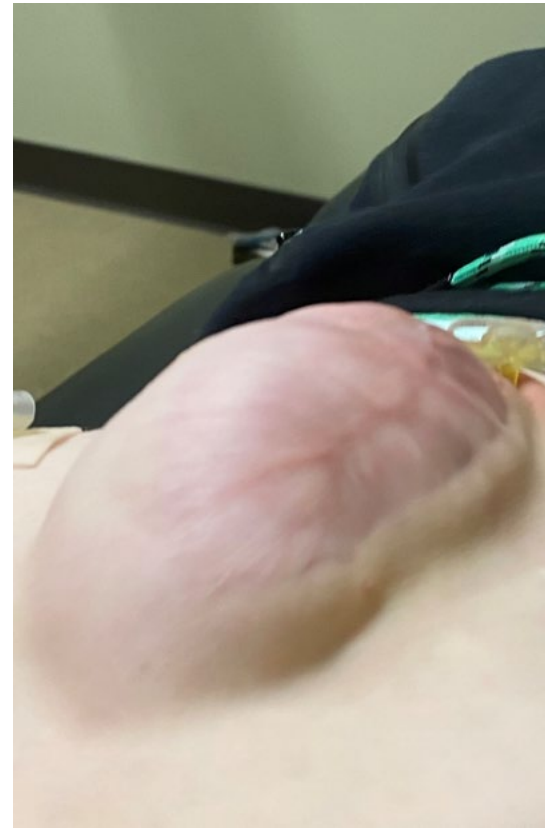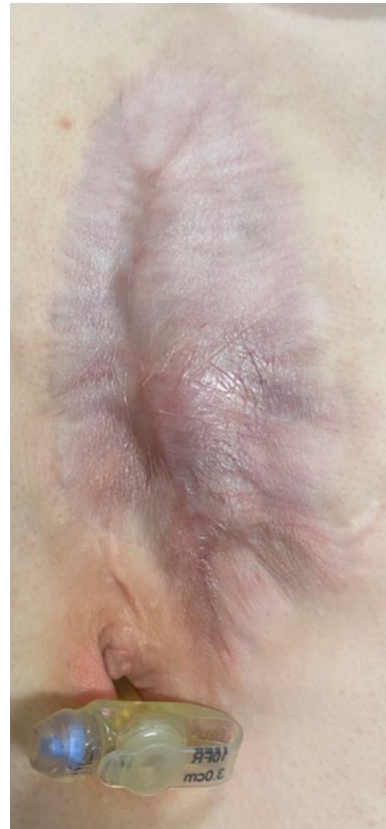


4/1/2022

### Hernia Pre-Surgery

Months later, the patient developed a hernia as a result of many prior abdominal surgeries.

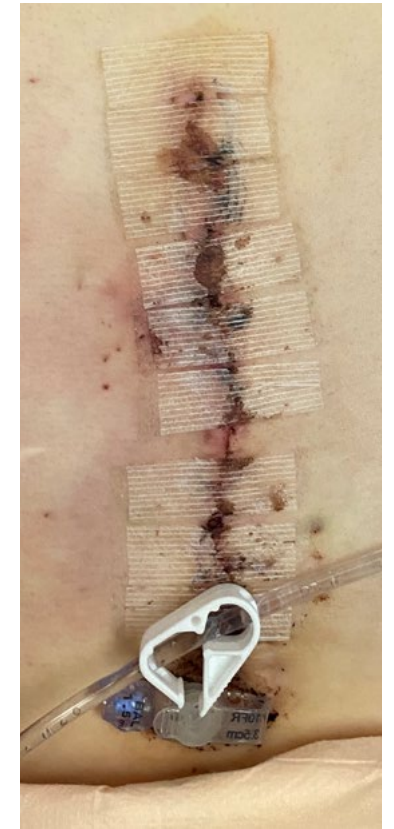The patient returned to the clinic for pre-surgical MLS Laser Therapy treatments to improve surgical outcomes.



4/6/2022

### Post-Hernia Repair

Expecting a complex procedure, surgeons were shocked at the healthy tissue and the hernia repair went smoothly.





**Before and After**

# **Treatment Images**

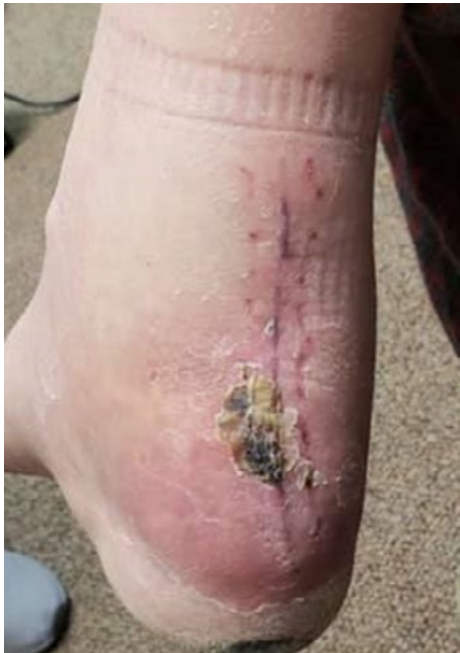Kile Kaspar, D.C. shares a selection of images that show the visible difference before and after MLS Laser Therapy treatments for wounds, ulcers, fractions, and more.

# Before and After Treatment Images

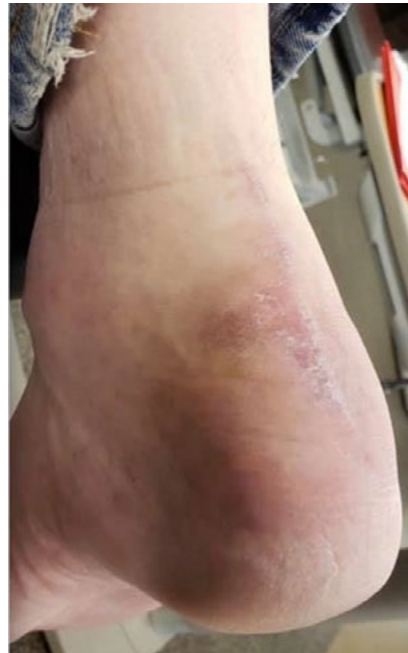## Post-Surgical Wound Healing

The patient's post-surgical wound was not healing after Achilles tendon repair so they began MLS Laser Therapy treatments.

**Before MLS Laser Therapy**



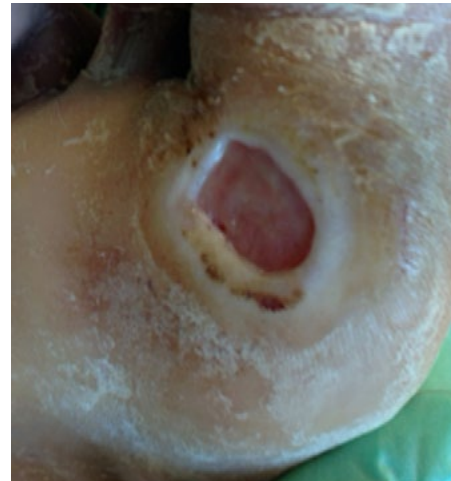**After 6 Sessions**



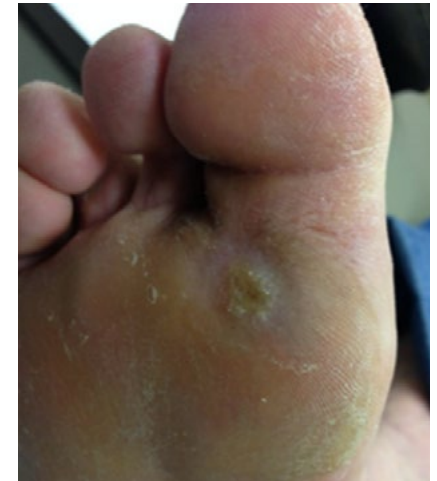## Diabetic Ulcer

After 15 months of aggressive podiatric wound care protocols, the patient's ulcer made little progress until they began MLS treatments.

**Before MLS Laser Therapy**




**After 5 Sessions**



Courtesy of Mickey Stapp, DPM in Evans, Georgia

[Watch the Video](#)



# Before and After Treatment Images

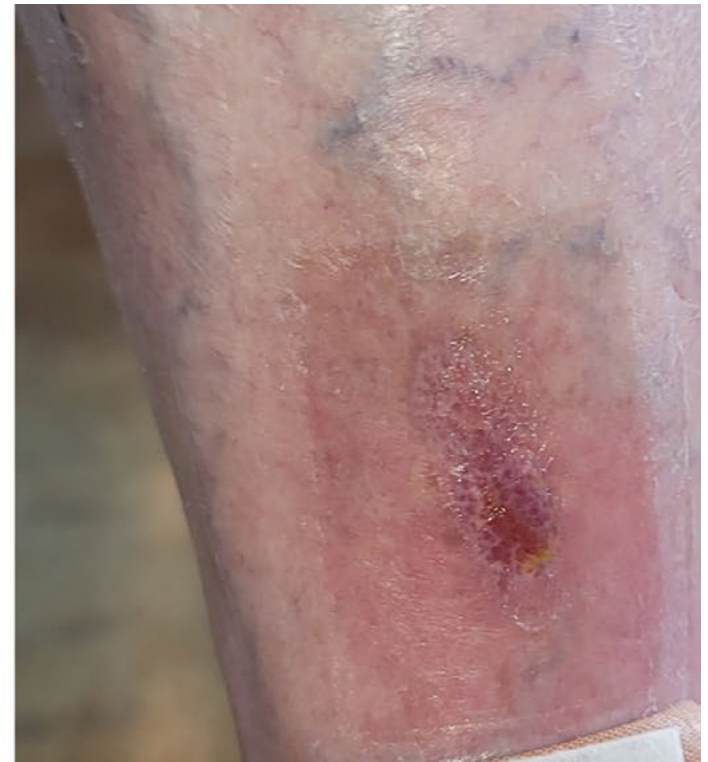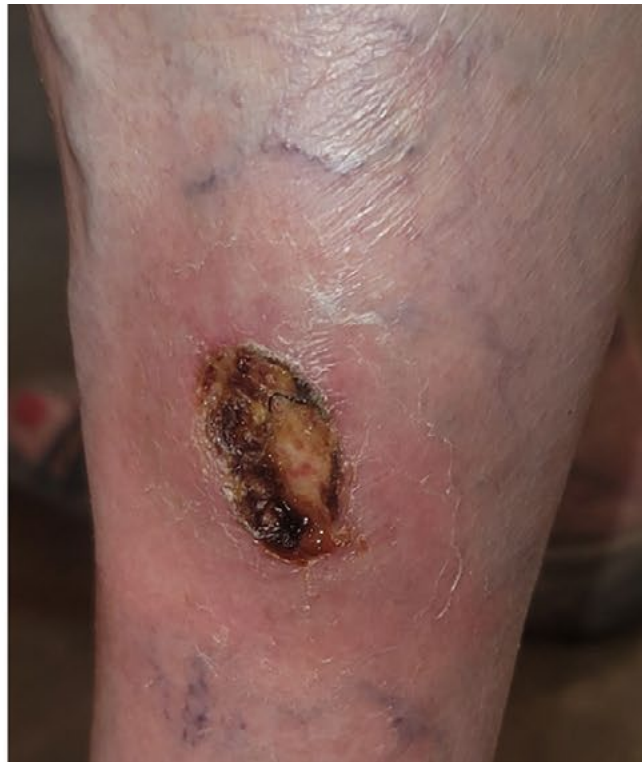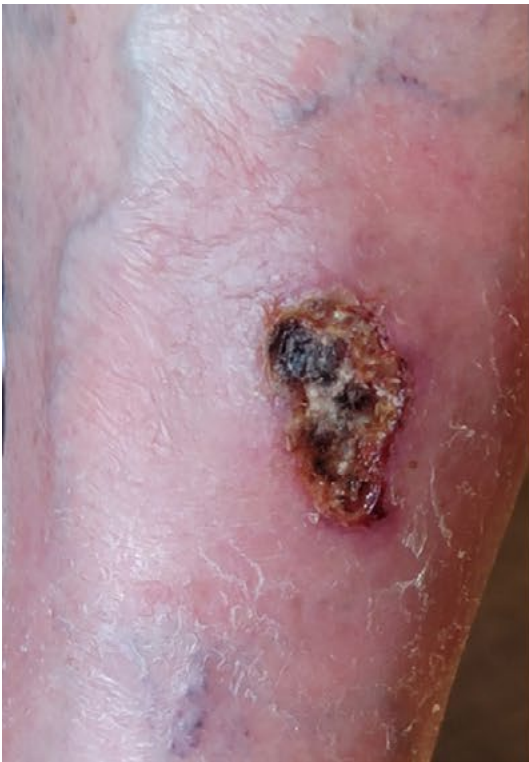## Wound Healing

The patient injured her leg on a fall. After attempting to treat it at home, the wound got out of control and the patient sought MLS Laser Therapy treatments at Dr. Kaspar's clinic.

**5/3/2022**

**5/10/2022**

**6/30/2022**



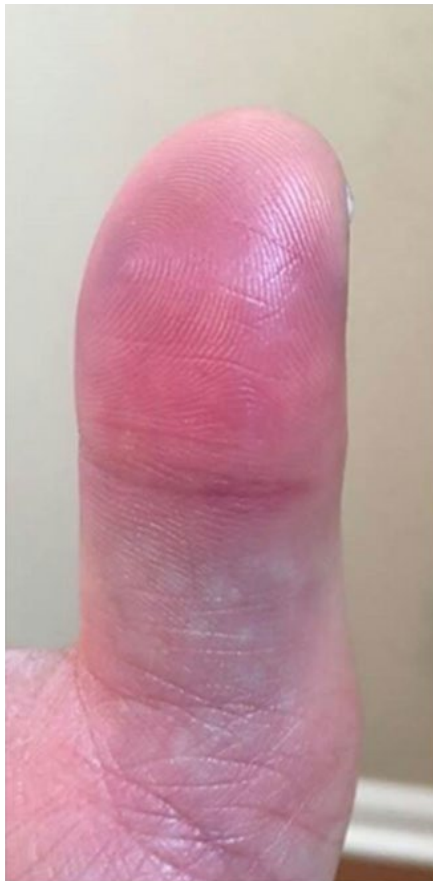
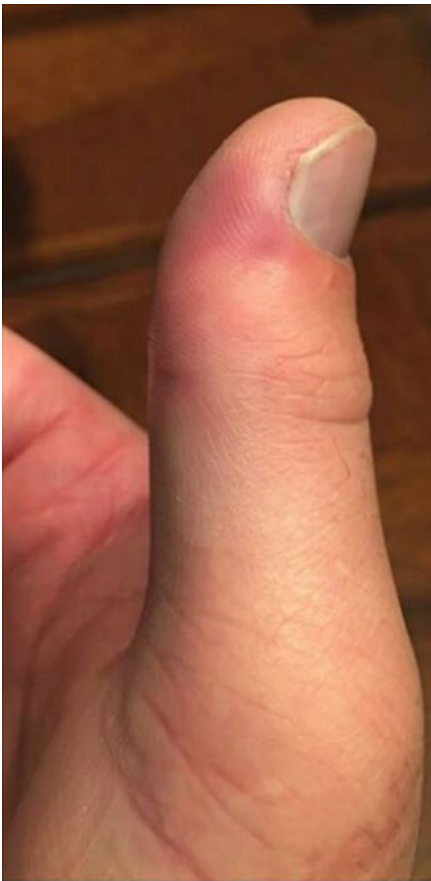
# Before and After Treatment Images

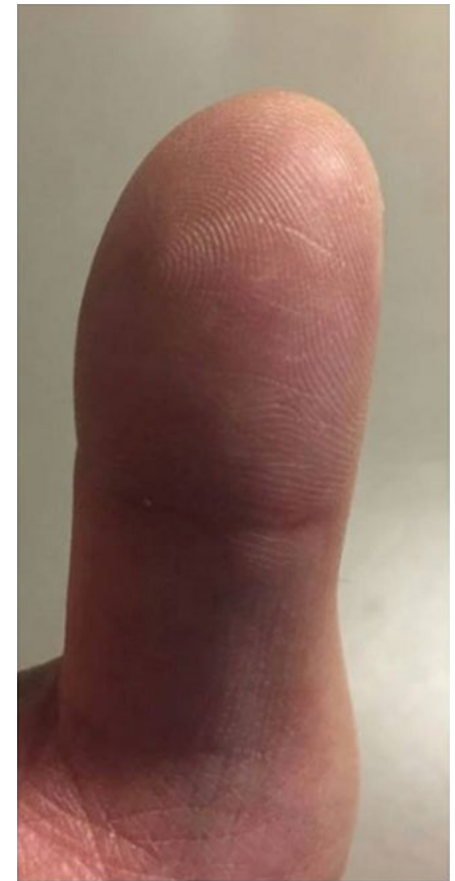
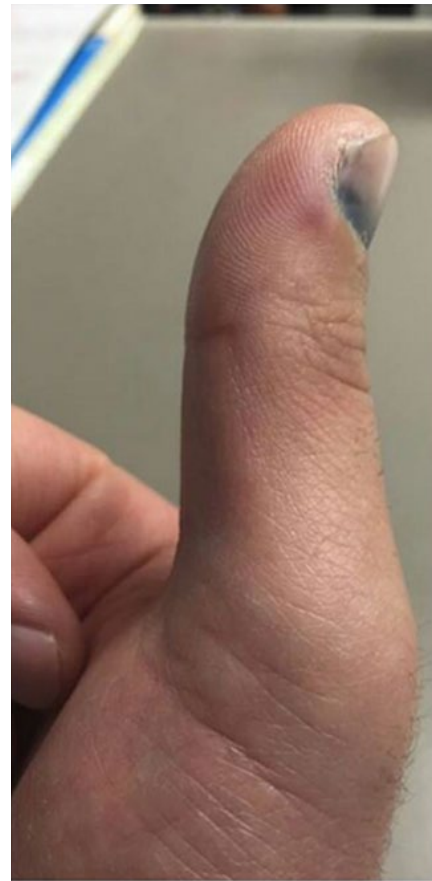
## Fracture

Doctors estimated this fracture would take 6 weeks to heal, but after 6 sessions of MLS Laser Therapy over 10 days the patient had no pain and was able to stop wearing his splint.

**Before MLS Treatment**



**After 6 Sessions**

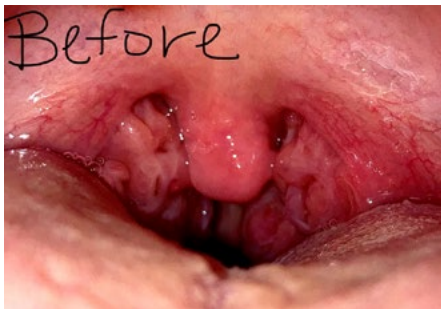

# Before and After Treatment Images

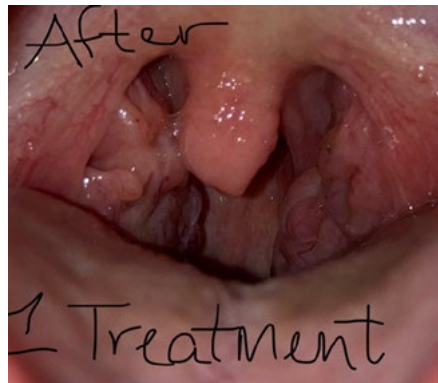## Chronic Tonsillitis and Apnea

A 16-year-old patient with chronic tonsillitis and chronic apnea began MLS Laser Therapy treatments and noticed results 12 hours after their first session.

**Before MLS Treatment**



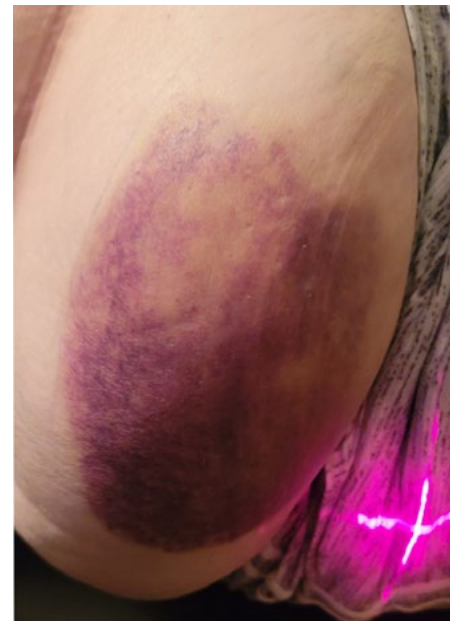**12 Hours After 1 Session**



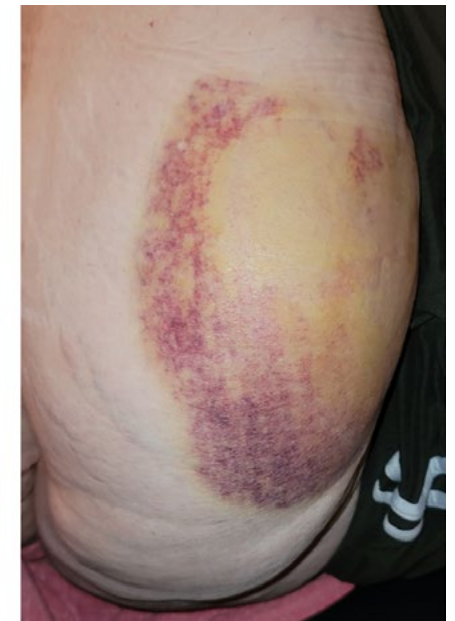## Contusions

One of Dr. Kaspar's regular patients, with a history of bruising easily, hurt her stomach on the edge of a metal lawn chair and requested MLS Laser Therapy to ease the pain.

**4/26/2022**



**4/28/2022**



**Find More MLS Laser Therapy Case Studies  
on the Cutting Edge Knowledge Center**



# Practice Benefits

Kile Kaspar, D.C. reviews the full scope of benefits that MLS Laser Therapy services can offer the chiropractic practice.

## MLS® Laser Therapy

# Benefits to the Practice

### ◆ Investing in Your Practice

When considering new treatment technologies for the practice, Dr. Kaspar reminds us that it's crucial to distinguish between cost and investment. Incorporating laser technology isn't just a cost; "It's an investment in yourself, your patients, and your financial future."

### ◆ Transitioning from Insurance to Cash

Shifting from insurance-based payments to cash services significantly transformed her practice. With insurance complexities increasing, pivoting to cash payments streamlined operations and allowed her practice to focus on cases where chiropractic intervention could truly make a difference.

"I went from 100% insurance to 95% cash in just over a year. Patients are willing to pay to feel better," shares Dr. Kaspar.

### ◆ Cash Flow and Service Value

Her successful transition to cash payments highlights the value patients place on effective treatment. Patients are willing to pay for results and relief from ailments. By offering laser therapy as a cash service, patients recognize its effectiveness and are eager to invest in their well-being.

Additionally, expanding treatment services allowed her practice to tap into patient populations that might not have otherwise considered chiropractic care.

### ◆ Time Freedom

One of the most rewarding aspects of integrating laser therapy into her practice is the newfound time freedom. Delegating laser therapy treatments to certified staff members allows Dr. Kaspar to reclaim valuable time, striking a balance between work and personal life.

### ◆ Treatment and Maintenance

Laser therapy is a versatile treatment option that offers a solution to a wide range of neuromusculoskeletal conditions. With fast and pain-free sessions, patients appreciate its convenience and effectiveness.

Research indicates that most conditions may require 6 to 24 treatment sessions. The interval is dependent on the patient's condition, however atypical treatment plan is 2 to 3 treatments per week for 4 to 8 weeks. Depending on the severity of the condition, 70% of patients respond after one treatment and 91% after three.

"And that is why they pay, refer, and keep coming back any time they injure themselves or have new complaint."

### ◆ Revenue Potential

Analyzing the revenue potential of laser therapy reveals substantial returns on investment. With a steady influx of new patients and strategic treatment plans, practices can see significant monthly revenue increases. Recovering the initial investment within six to nine months is achievable, paving the way for long-term profitability and practice growth.

"If you just had one new patient a day on a 6 to 12 visit treatment plan, you're going to have 200 to 300 additional visits monthly," Dr. Kaspar shares from experience. "The return on the investment is anywhere between \$12,000 to \$25,000 extra a month revenue... Most doctors could recover their investment in 6 to 9 months."

MLS Laser Therapy offers a myriad of benefits for both patients and chiropractic practices alike. Patients experience comprehensive pain relief and accelerated tissue repair through the advanced technology of Class IV lasers, leading to improved quality of life.

For chiropractors, integrating MLS Laser Therapy into their practice not only enhances patient care but also streamlines treatment delivery with its automated emission system. The precision, consistency, and safety offered by MLS Laser Therapy make it a valuable addition to any chiropractic practice. Embracing technologies like MLS Laser Therapy demonstrates a commitment to staying ahead in the field, attracting patients seeking innovative treatments and ultimately contributing to the success and growth of the practice.

By leveraging the latest advancements, chiropractors can position themselves at the forefront of healthcare, ensuring both patient satisfaction and practice prosperity in the ever-evolving landscape of modern medicine.

Visit [celasers.com](http://celasers.com) to learn more about the benefits MLS Laser Therapy.

